



Evaluation of Clinical Outcomes of Various Materials Used for Apexification in South Asia: A Systematic Review

**R Jesanth Joel ^{a++*}, Swathi Priyadharshini ^{b#},
I Anand Sherwood ^{at}, Vaanjay M ^{a‡}, Rathna Piriyaanga ^{c^}
and A Azhagu Abirami ^{a‡}**

^a Department of Conservative Dentistry and Endodontics, CSI College of Dental Sciences and Research, Madurai, Tamil Nadu – 625001, India.

^b Department of Conservative Dentistry and Endodontics, Saveetha Dental college, Poonamallee, Chennai – 600077, India.

^c CSI College of Dental Sciences and Research, Madurai, 625001, India.

Authors' contributions

This work was carried out in collaboration among all authors. All authors read and approved the final manuscript.

Article Information

Open Peer Review History:

This journal follows the Advanced Open Peer Review policy. Identity of the Reviewers, Editor(s) and additional Reviewers, peer review comments, different versions of the manuscript, comments of the editors, etc are available here: <https://www.sdiarticle5.com/review-history/115528>

Systematic Review Article

Received: 04/02/2024

Accepted: 08/04/2024

Published: 11/04/2024

ABSTRACT

Background: Endodontic treatment encounters challenges, especially with open tooth apices affected by trauma or pulpal pathology, resulting in divergent or flaring root walls known as "Blunderbuss" or "non-blunderbuss" canals. Conventional root canal procedures for managing open

⁺⁺ Post Graduate;

[#] MDS, Research Scholar;

[†] MDS, PhD, Professor and Head of the Department;

[‡] MDS, Senior Lecturer;

[^] MDS, Reader;

^{*}Corresponding author: Email: jesanthjoel96@gmail.com;

apices have a risk of material extrusion. Notably, there is a lack of documented analysis on materials and methods for apexification in South Asian countries, highlighting a gap in research within the field.

Aim: This paper aims in providing a comprehensive review of various materials and methods utilized in apexification procedures in South Asian countries.

Materials and Methods: This systematic review, from January 2000 to August 2023, employed a thorough computerized search on apexification procedures in South Asian countries. Utilizing keywords, articles from Google Scholar and PubMed databases were examined using Boolean operators. Following inclusion and exclusion criteria the articles were screened and 8 articles were selected, fully read, and analysed in association with the review question.

Results: From the chosen articles, three primary materials—Calcium Hydroxide, MTA, and Biodentine were prominently used in apexification procedures. Notably, Biodentine demonstrated superiority over the other materials, while Calcium Hydroxide was identified as the gold standard for apexification in teeth with shorter roots. **Conclusion:** The conducted studies distinctly point Biodentine as a preferred material for apexification in South Asian countries. Nevertheless, further studies have to be made within the region to enhance understanding of apexification procedures and explore newer materials available.

Keywords: Apexification; immature apex; Calcific bridge; biodentine; mineral trioxide aggregate; calcium hydroxide.

1. INTRODUCTION

Apexification is a critical aspect of endodontic treatment that encounters various challenges, one of which involves dealing with open tooth apices [1]. Root development typically completes within three years after eruption, facilitated by Hertwig's Epithelial Root Sheath (HERS), which forms the apical foramen. An open apex indicates inadequate root development, resulting in a lack of the conical taper necessary for normal function. Trauma or pulpal pathology can impede this process, leading to divergent and flaring root walls, creating a wider, funnel-shaped apex known as a "Blunderbuss canal," or slightly convergent walls referred to as a "non-blunderbuss canal" [2]. Managing an open apex poses challenges during conventional root canal procedures due to the increased risk of filling material extrusion beyond the apex.

Apexification is a technique aimed at encouraging the formation of a calcific barrier within the open apex of an immature tooth with non-vital pulp, thereby confining filling material within the root canal space [3]. Traditionally, a multi-visit approach employing Calcium Hydroxide has been considered the most effective for apexification. Studies have indicated that the time required for calcium hydroxide to establish a calcific barrier range from 5 to 20 months [4]. Presently, in cases where sufficient root length exists, clinicians opt for a single-visit apexification method involving the non-surgical introduction of a biocompatible material into the

root apex, serving as the apical barrier for future filling material [5]. Various materials have been employed for apexification procedures, including Calcium Hydroxide and calcium silicate-based substances like Mineral Trioxide Aggregate (MTA) Pro-Root (Dentsply, Mallifer, Switzerland), METAPEX (Meta Biomed Co. Ltd., South Korea), and biodentine (Septodont, Saint-Maur-des-Fossés, France).

Calcium Hydroxide has been widely utilized due to its capacity to trigger the expression of several proteins, notably Bone Morphogenetic Protein (BMP) and Transforming Growth Factor Beta One (TGFβ1), which promote dentinogenesis at the root apex [6]. Meanwhile, Mineral Trioxide Aggregate (MTA) demonstrates hydrophilic and biocompatible properties, stimulating healing and bone regeneration in cases of root resorption. Although both MTA and calcium hydroxide are commonly employed in treating immature teeth with open apex, Biodentine, with its shorter setting time compared to MTA, is gaining preference among some clinicians [7].

This paper provides a comprehensive review of various materials utilized in apexification procedures and the diverse methods employed in South Asian countries. The objective is to analyse the clinical outcomes of treating immature apex teeth based on the materials and methods outlined in the selected studies. This review aims to offer, high-quality evidence regarding the efficacy of Apexification techniques concerning the materials and methodologies used specifically within South Asia.

2. MATERIALS AND METHODS

2.1 Review Question

This systematic review is adhered to the guidelines outlined by the Preferred Reporting Items for Systematic Reviews and Meta-Analyses (PRISMA). This review was registered in PROSPERO International prospective register of systematic reviews (ID: CRD42023471863) The primary question driving this review was: "What are the clinical outcomes associated with different methods of apexification in teeth with immature apex conducted in South Asian countries?" and the secondary question to be that, "what radiographic observations can be identified following the use of included materials postoperatively?" The review question was structured in accordance with the Participants, Intervention, Comparison, and Outcome (PICO) format.

Participants/Population (P): Children, Adolescents and people of up to 25 years of age in South Asian countries who visit the endodontic department for the treatment of both mature and immature apex where apexification procedure is done.

Intervention (I): Apexification procedure performed with MTA, METAPEX, Biodentine.

Comparison (C): Calcium Hydroxide Ca (OH)₂.

Outcome (O): Clinical and radiographic evaluation of continued root development, Increased bone Healing, Radiographic Periapical Healing.

2.2 Eligibility Criteria

2.2.1 Inclusion and exclusion criteria:

The inclusion criteria are as follows:

1. Randomized control clinical trials
2. Case reports
3. Case series
4. Observational studies

The exclusion criteria include:

1. Invitro studies
2. Animal studies
3. Apexification studies outside South Asia.
4. Apexogenesis studies.

2.2.2 Search methodology

This systematic review was initiated through a comprehensive computerized search encompassing case report, case studies, randomized controlled clinical trials, and observational studies focused on apexification procedures employing various materials and methods for treating immature apices in South Asian countries. The search has covered articles published on Google Scholar and PubMed databases from January 2000 to August 2023. Boolean operators were utilized to refine the search and eliminate unnecessary or inappropriate results.

The search strategy employed a combination of keywords related to the topic Clinical Outcome OR Results OR Success Rate OR Radiographic Evaluation OR Clinical Evaluation OR Calcific plug OR Hard tissue formation OR apex formation OR root growth AND METAPEX OR PRF OR Blood clot OR Apical over-instrumentation OR Apexification OR Regenerative Endodontic Procedure OR Immature Apex OR traumatized young tooth AND India OR Maldives OR Pakistan OR Bangladesh OR Nepal OR Sri Lanka OR Afghanistan OR Bhutan OR British Indian Territory OR South Asia OR Clinical Trial OR Randomized control Trial. Only studies published in English were considered for inclusion in this review.

Abstracts and titles of potentially significant studies were meticulously identified for relevance before retrieving the full text of each article. To enhance comprehensiveness, additional manual searches were conducted on the volumes and issues of key journals, including thorough examination of indexes and special issues. Three independent reviewers participated in the review process, assessing both abstracts and full-text articles. In instances where disagreements arose, consensus meetings were convened to resolve any differences among the reviewers. This collaborative approach ensures a rigorous and reliable evaluation of the selected studies.

India has emerged as the leading contributor among South Asian countries in the treatment of Immature Apex, with a total of six studies included among the reviewed research. The present article encompasses all types of studies, with the exception of reviews, to enhance the significance of outcomes within this systematic review. By incorporating diverse study types, this

approach aims to furnish clinicians in South Asian countries with comprehensive insights into the advantages and drawbacks associated with commonly utilized materials in apexification procedures for treating immature apex conditions.

2.3 Quality Assessment of Included Studies

The assessment of the included studies' quality was conducted using Robvis, a visualization tool developed in April 9 at the Evidence Synthesis Hackathon (ESH), an event which brings together interested researchers, practitioners, and coders to discuss and develop new open-source evidence synthesis technologies [8]. Robvis features two main plots: the traffic light plot and the weight bar plot. It incorporates five domains corresponding to potential biases arising from the randomization process (D1), deviations from the intended intervention (D2), missing outcome data (D3), data outcome bias (D4), and selection bias in reporting results (D5). A study is categorized as having a high or low

risk of bias based on the presence or absence of variables within these domains. This robust evaluation provides a comprehensive understanding of the quality of the included studies. (Table 1). The included 8 articles for are of potentially low risk according to robvis tool and have been discussed in the following systematic review. The quality assessment of the included studies has been provided in (Table 1).

Based on the information provided, a thorough analysis of eight articles was conducted by reviewers using the Robvis visualization tool. This tool allowed them to assess the quality of the articles based on different domains. The reviewers categorized each domain as either high risk, low risk, or some concerns, depending on the level of risk identified in each domain. After the assessment, the Robvis tool generated a quality assessment table, which provided an overall assessment of low risk across the domains. This indicates that, overall, the articles were deemed to have a low risk of bias or other quality concerns according to the assessment criteria used.

Table 1. Quality assessment of included studies

		Risk of bias domains					
		D1	D2	D3	D4	D5	Overall
Study	study 1						
	study 2						
	study 3						
	study 4						
	study 5						
	study 6						
	study 7						
	study 8						

Domains:
 D1: Bias arising from the randomization process.
 D2: Bias due to deviations from intended intervention.
 D3: Bias due to missing outcome data.
 D4: Bias in measurement of the outcome.
 D5: Bias in selection of the reported result.

Judgement
 Low

3. RESULTS

The chosen studies were acquired from Google Scholar and PubMed and were imported into the Rayaan AI database (<https://www.rayaan.ai/>). The evaluation focused on articles addressing Apexification, considering clinical outcomes, success rates, calcific plug formation, continued root growth, and dentin barrier development. Initially, 8015 articles were uploaded, with the removal of duplicate records (104 articles), leaving 7911 records for screening. After excluding 7857 articles, 54 were identified as eligible. Of these, 32 articles were included for review with unanimous agreement among the reviewers. A thorough examination of the selected articles took place, excluding those without a significant control group. Case reports within the selected articles underwent evaluation for both clinical and radiographic outcomes, such as complete root growth during the follow-up period and proper apical closure. Cases that did

not provide desired results were excluded. The final systematic review comprised 8 articles, encompassing randomized control trials, case reports, case series, and clinical trials published by four South Asian countries.

PRISMA flowchart (Fig1.) explains the selection procedure. The reason for exclusion is given in (Table 4). The 8 studies that are included for the study are one randomized control trial (Damle SG, Bhattal H, Loomba A 2012 [9], five case reports (Navroop kaur Bajwa, Anuradha Pathakar 2015 [10], Dr. Josey Matthew, Dr. Gibi Syriac, Dr. Manuja Nair, Dr. Rahul J 2017, [11] R Nahar, F Chowdary, M.K. Alam 2018,[12] Ruaz, Rafia 2022,[6] N Sridhar, Shoba Tandon. 2010 [13], One clinical trial (S. Pavula et al. 2024), One case series (Sharma et al. 2018 [14] whose characteristics are given in (Table 3). The articles mainly focus on materials which can be used effectively for apexification procedure (Table 2).

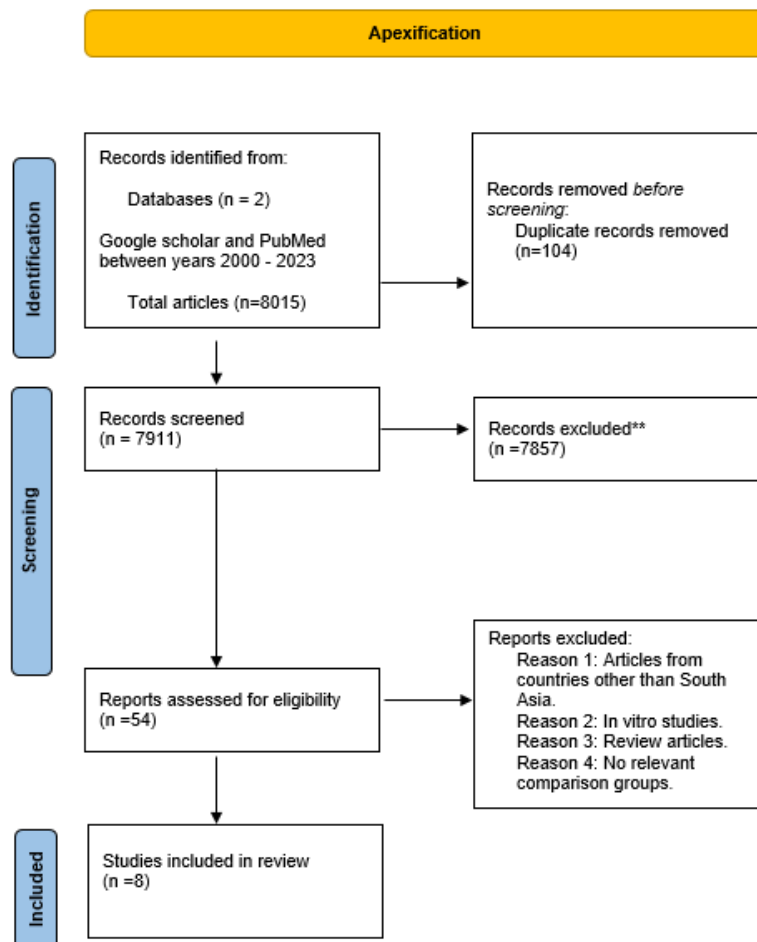


Fig. 1. Flowchart of process of inclusion

Table 2. Frequency of South Asian countries involved and materials used for apexification

Frequency of countries involved	Frequency of materials used
BANGLADESH – 1	BIODENTINE - 2
INDIA – 6	CALCIUM HYDROXIDE - 3
PAKISTAN – 1	METAPEX - 1
	MTA - 2

The features of included studies are given in (Table 3) in which most commonly used three materials namely Calcium Hydroxide, MTA and biodentine for apexification. Out of the studies selected, calcium Hydroxide was proven as a gold standard material for teeth with incompletely formed roots, whereas MTA and biodentine showed better clinical and radiographic outcomes in terms of healing and apical plug formation. Biodentine is the superior material among all the three materials by a minor margin over MTA (Fig. 2.)

3.1 Assessment of Success Rates

3.1.1 Calcium hydroxide Ca (OH)₂ vs MTA vs biodentine

All the included articles focused on reporting the success rates of three widely utilized materials for apexification: Calcium Hydroxide [Ca (OH)₂], Mineral Trioxide Aggregate (MTA), and Biodentine. Success rates were determined

based on radiographic calcific bridge formation and proper apical closure, with an average follow-up time of 6-12 months. The efficacy of calcium hydroxide apexification is attributed to its alkaline pH of 10.5. calcium hydroxide took an average time of 7.93 months for barrier formation, with a reported failure rate of 1 in every 15 teeth undergoing calcium hydroxide apexification [15]. The alkaline pH of calcium hydroxide facilitates the formation of a calcium proteinate bridge, inhibiting phospholipase enzymes and reducing inflammation in the periapical region. It also induces cell differentiation at the apical third of the tooth, making it a gold standard material for apexification in teeth with immature apices lacking sufficient root growth [16]. When combined with Iodoform paste, calcium hydroxide forms METAPEX (Meta Biomed Co. Ltd., South Korea), which may not show significant barrier formation but can be used as a medication to promote root growth [12].

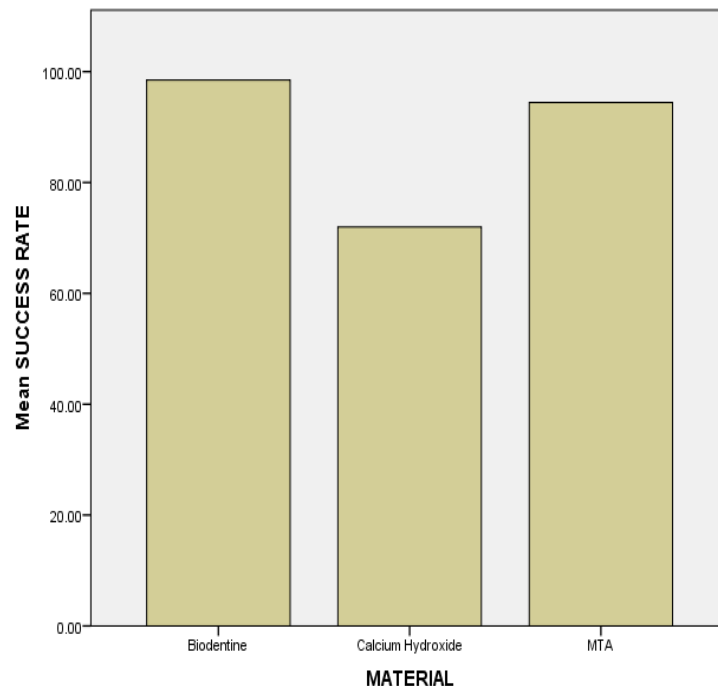


Fig. 2. Comparison of success rates of materials used for apexification in the included studies

Table 3. Characteristics of included studies

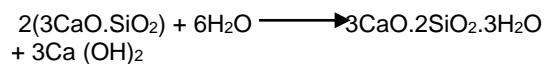
TOPIC	JOURNAL	AUTHOR	YEAR OF PUBLICATION	COUNTRY	MATERIALS USED	METHODS	TYPE OF STUDY	SAMPLE SIZE	TIME OF FOLLOW UP	DIAGNOSIS	OUTCOME	PECULIARITY OF THE STUDY
Apexification of anterior teeth: a comparative evaluation of mineral trioxide aggregate and calcium hydroxide paste.	The journal of clinical pediatric dentistry	Damle SG, Bhattal H, Loomba A	2012	India	Mineral Trioxide Aggregate, Calcium Hydroxide	Apexification	Randomized control trial	30	3,6,9,12 months	Pulp necrosis	MTA Showed better clinical outcome than Ca (OH)2	A single tooth treated with Ca (OH)2 showed internal resorption
Single Visit Apexification Procedure of a Traumatically Injured Tooth with a Novel Bioinductive Material (Biodentine)	International Journal of clinical pediatric Dentistry	Navroop kaur Bajwa, Mahesh Madhukar Jingarwar, Anuradha Pathakar.	2015	India	Biodentine	Apexification	Case Report		1 month	Ellis Class IV fracture	Biodentine shows better efficiency than other apexification materials.	
Saudi Journal of Oral and Dental Research Conventional Multivisit Calcium Hydroxide Apexification with Rare Apexogenesis Like Outcome and Novel Single Visit MTA Apexification Followed by Root Reinforcement with Fiber Post: Two CASE REPORTS	Saudi Journal of oral and dental research	Dr. Josey Mathew, Dr. Gibi Syriac, Dr. Manuja Nair, Dr. Rahul J	2017	India	Calcium Hydroxide and MTA	Apexification	Case Report	2	6 months	Pulp necrosis	MTA is proved a better apexification material than Ca (OH)2	
Apexification with the use of calcium hydroxide	Bangladesh Journal of Medical Science	R Nahar, F Chowdary, M.K. Alam	2012	Bangladesh	Calcium Hydroxide	Apexification	Case Report	1	3 months	Ellis Class IV fracture	Calcium Hydroxide induces cytodifferentiation at the apex causing continued root development.	
Large Periapical or Cystic Lesions in Association with Roots Having Open Apices Managed Nonsurgically Using 1-step Apexification Based on Platelet-rich Fibrin Matrix and Biodentine Apical Barrier: A Case Series	Journal of endodontics	Sharma et al.	2018	India	Biodentine	Apexification	Case series	3	3 months	periapical abscess	Placing biodentine barrier below PRF showed significant decompression of the periapical cystic lesions.	Teeth with periapical cystic lesions are included.
Efficacy of Calcium Hydroxide and Mineral Trioxide Aggregate in the Formation of Dentin Bridge - A Randomized Controlled Trial	Journal of the pakistan Dental Associaton	Ruaz, Rafia	2022	Pakistan	MTA, Calcium Hydroxide	Apexification	Case Report	100	3-6 months	Pulp necrosis	MTA forms a stronger dentin Bridge than Calcium Hydroxide	
Continued Root-End Growth and Apexification Using a Calcium Hydroxide and Iodoform Paste (Metapex®): Three Case Reports	The Journal of contemporary Dental practice	N Sridhar, Shoba Tandon.	2010	India	Calcium Hydroxide and Iodoform paste (METAPEX)	Apexification	Case Reoprt	3	12 months	Pulp necrosis	METAPEX shows both apical closure and continued root end development radiographically.	METAPEX usage
Cone-beam computed tomographic evaluation of biodentine apexification for traumatized necrotic immature permanent incisors: One-year clinical study	Endodontology	S. Pavula et al.	yet to be published	India	Biodentine	Apexification	Clinical trial	85	12 months	Pulp necrosis	Biodentine has the ability to deposit hard tissue three dimensionally.	CBCT evaluation

Table 4. Reason for exclusion of studies

REASON FOR EXCLUSION	NUMBER OF ARTICLES	AUTHOR
Review	7	Godhi et al.2023, Abdulquader et al.2011, Dali et al. 2014, Arshad et al.2021, Shafiqul et al.2021, Shetty et al.2019, Ghosh et al.2014
Unavailable	1	BAS et al.2022
Duplicates	1	Santhakumar et al. 2018
In vitro studies	4	Ham et al.2005, Tolibahh et al.2022, Darak et al.2020 Sogukpinar et al.2020
Methodology	20	Jadhav et al.2012, Santhakumar M et al.2018, Shah N et al.2008, K Biswas et al.2019, Singh et al.2019, Naithini et al.2015, Khetarpal et al.2013, Samsudinn et al.2021, Ghafoor et al.2012, Pandey et al.2016, Kumar et al.2014, Nguyen et al.2014, Singh Thakur et al.2020, Pathak et al.2020, Rj,Pradhan 2009, Vasavada et al.2020, Saleem et al,2023, Pradhan et al.2019, Afroz khan et al. 2021, Halim et al.2022

Mineral Trioxide Aggregate (MTA) forms a healthy dentin bridge at the apical third and preserves tooth vitality if the pulp is not necrotic. MTA is biocompatible and induces matrix formation and mineralization, causing odontoblast differentiation and forming hard tissue at the apical third of the teeth. MTA exhibits a dentin bridge formation rate of 0.23 micrometers per day, particularly high in the 27 to 48 days after apexification (3.5 micrometers per day). MTA demonstrated significantly accelerated barrier formation due to significant release of calcium ions and inducing cell proliferation at the apical third of the root with a mean time of 4-5 months and no failures highlighting its comparative success rate (92-97%) over calcium hydroxide, which is approximately 90% [13].

Biodentine is a calcium silicate-based material that induces micromechanical bonding by forming crystals deposited between dentinal tubules [17]. The complete hydration reaction is represented by,



Furthermore, Biodentine exhibits superior adaptability at the root end compared to MTA, nearly eliminating the impact of microleakage. Biodentine claims higher success rates, excellent bio adaptability, and remarkable properties for hard tissue deposition, while being less technique-sensitive than any other materials in Apexification. Radiographically, Biodentine achieves uniform sealing of the apical third and attains sufficient radiographic thickness in a shorter duration compared to MTA. Notably, Biodentine has been shown to enhance both Root Length (RL) and Radiographic Root Area (RRA). Recent research, by Dr S. Pavula et al., indicates a significant increase in root length by up to 2mm and an increase in radiographic root area by up to 15 mm². This suggests that Biodentine can be a viable option for apexification in teeth with insufficient root lengths [10].

4. DISCUSSION

Apexification is a rapidly emerging procedure in the field of Regenerative Endodontics with newer materials in an attempt to save an immature tooth with open apex. Some South Asian countries (Table 2) have made several clinical trials, case reports and case series to evaluate

the outcomes and drawbacks of various apexification. This review conducted a comprehensive comparison of outcomes associated with different materials and methods employed for apexification in South Asia, specifically focusing on the treatment of teeth with immature apex. The study highlighted the three most commonly used materials in this context: Calcium Hydroxide, Mineral Trioxide Aggregate, and Biodentine. The primary findings reveal that, among these materials, Biodentine demonstrated superior results with minimal adverse effects, as illustrated in Fig. 2. This underscores the potential of Biodentine as a preferred choice in the apexification process for teeth with immature apices in the South Asian region.

As per Guerrero et al., Calcium Hydroxide has demonstrated an impressive 74 to 100% apical barrier formation. Upon contact with connective tissue, it induces superficial necrosis with a thickness of up to 1-1.5mm. Within this necrotic zone, fibroblastic cells generate a fibrous matrix, forming tubular dentin, also known as orthodentine [18]. In teeth with incompletely formed roots, Calcium Hydroxide promotes a significant amount of root growth. However, prolonged contact of Calcium Hydroxide with exposed dentin can compromise the intrinsic properties of dentin, potentially leading to root fracture before the completion of treatment [9].

Histologically, Calcium Hydroxide (Ca (OH)₂) has been observed to increase Bone Morphogenetic Protein BMP-2 at the root level. BMP-2 is known to stimulate the regeneration of bone, cementum, and the periodontal ligament in dogs. Numerous studies indicate that BMP-2 deposited by Calcium Hydroxide triggers osteoblastic activity, resulting in a notably stronger apical plug that continues to develop apically on the root surface [19]. This highlights the multifaceted impact of Calcium Hydroxide at both the histological and clinical levels in the context of apexification.

MTA Pro-Root (Dentsply, Mallifer, Switzerland) [15] serves as a valuable alternative to Calcium Hydroxide for forming an apical seal. Comprising Dicalcium Silicate, Tricalcium Silicate, Tricalcium Aluminate, and Bismuth Oxide, MTA's free crystalline silicate content enables the formation of a substantial apical plug in a single visit [20]. MTA addresses various limitations associated with Calcium Hydroxide in apexification. Notably, MTA offers advantages such as reduced

treatment time, expedited simulation of apex repair, and excellent biocompatibility. However, a notable drawback in MTA apexification lies in the challenge of limiting the material to the apical third. Its difficulty in manipulation and the extended time required for hardening are significant considerations [21]. MTA has been demonstrated through radiographic and microscopic examination to exhibit superior adaptation with fewer voids than the ultrasonic method. However, MTA's higher cost and its sandy consistency when hydrated can pose challenges in manipulation [22]. Despite these challenges, MTA stands out as a promising option, providing enhanced efficiency and biocompatibility in comparison to Calcium Hydroxide for achieving successful apexification.

Biodentine, (Septodont, Saint-Maur-des-Fossés, France) [21] has emerged as a notably more efficient apexification material compared to others. Its exceptional adaptability to underlying dentin is attributed to micro adhesion and the precipitation of hydroxyapatite crystals at the root level, effectively reducing marginal percolation of periapical fluids [14]. The success rates of apexification procedures using various materials, including Calcium Hydroxide, Mineral Trioxide Aggregate (MTA), and Biodentine hinge on the deposition of hard tissues and the achievement of significant apical foramen closure. A recent study by S. Pavula et al., 2024 employed 3D analysis of dentine volume changes in Biodentine apexification procedures, revealing its capacity to deposit hard tissue three-dimensionally. According to the study, the success rates for apexification using Calcium Hydroxide, Mineral Trioxide Aggregate (MTA), and Biodentine are reported as 89.47%, 94.25%, and 98.46%, respectively (see Fig. 2) [10]. These findings underscore Biodentine's superior performance in promoting successful apexification, making it a promising choice in clinical practice.

Calcium Hydroxide apexification demonstrates commendable success rates; however, some teeth subjected to apexification using calcium hydroxide exhibit internal resorption. This occurrence is attributed to calcium hydroxide inducing initial superficial necrosis of the predentin at the apical third, subsequently exposing dentin to odontoclast cells and resulting in resorption [23]. Furthermore, calcium hydroxide exhibits material resorption at the apical level, making apexification with it impractical for a single-visit procedure. There are

several drawbacks associated with calcium hydroxide apexification. This process necessitates the frequent replacement of medication over a period of 5-20 months. The unpredictable and protracted nature of this treatment, coupled with the use of a temporary coronal restoration that may fail during the course, heightens the risk of re-infection. A permanent restoration cannot be applied until apexification is complete. The incidence of cervical root fractures is elevated in teeth undergoing calcium hydroxide apexification, attributed to thin dentinal walls and a compromised tooth structure induced by the calcium hydroxide treatment. Moreover, successful outcomes rely heavily on a high level of patient compliance. [11]

On the other hand, Mineral Trioxide Aggregate (MTA) has a lengthier setting time of 2 hours and 45 minutes, introducing a high risk when placing any restorative material over an MTA apical plug. Additionally, the placement of MTA is highly technique-sensitive, posing challenges in manipulation at the apical root level. These factors contribute to the complexity and potential drawbacks associated with MTA in the context of apexification procedures.

In summary, the systematic review concludes that Biodentine is the superior choice for apexification due to its favorable properties, ease of manipulation, and positive clinical outcomes. Extensive studies highlight its heightened biocompatibility and potential as a biologically active dentin replacement. While MTA shares similar properties, Biodentine shows minimal to no side effects, making it more preferable. However, Calcium Hydroxide has always been preferred for teeth with immature apex and shorter roots due to its continued root growth promoting potential. Despite Calcium Hydroxide's historically gold standard status, it exhibits lower success rates than MTA and Biodentine. Nevertheless, it remains relevant, especially for cases involving teeth with shorter roots, due to its promotion of continued root development and calcific plug formation. Biodentine enhanced the survival and differentiation of stem cells of the apical papilla (SCAP), along with an upsurge in the odontoblastic marker DSPP, thereby facilitating the closure of open-apexed root canals and promoting peri-apical healing. Conversely, MTA seemed to induce increased osteoblastic differentiation as evidenced by heightened expression of the osteoblastic marker Integrin Binding Sialoprotein (IBSP) [24].

Khanduri et al. (2021) concluded in their study that the utilization of Biodentine for establishing a calcific apical barrier represents a novel approach in apexification. The excellent biocompatibility, hydrophilic nature, enhanced sealing ability, and rapid setting time of Biodentine position it as a promising material for accomplishing single-visit apexification procedures [25].

5. CONCLUSION

Apexification stands out as an effective approach in managing teeth with immature open apices, evolving from the multi-visit calcium hydroxide technique to the single-visit methods involving MTA and Biodentine. Recent efforts focus on combining apexification with revascularization procedures for improved outcomes in treating immature apices. While India has made significant contributions in South Asia to the field of apexification, further research across various South Asian countries with newer materials is essential to enhance strategies in this domain.

CONSENT AND ETHICAL APPROVAL

It is not applicable.

ACKNOWLEDGEMENT

Gratitude to God for guidance. Thanks to mentors, colleagues, and supporters for invaluable contributions.

COMPETING INTERESTS

Authors have declared that no competing interests exist.

REFERENCES

1. Dawoud A, Elboraey M. Clinical and CBCT comparison of MTA revascularization versus apexification for immature permanent incisors. *Egyptian Dental Journal*. 2022;68(4):3041-54.
2. Shobhana R, Prakash V, Venkatesh A, Vivekanandhan P. A Review on management of open apex in permanent teeth. *Int. J. of Aquatic Science*. 2021;12(3):2055-61.
3. Huang GJ. Apexification: The beginning of its end. *International Endodontic Journal*. 2009;42(10):855-66.
4. Agrafioti A, Giannakoulas DG, Filippatos CG, Kontakiotis EG. Analysis of clinical studies related to apexification techniques. *Eur J Paediatr Dent*. 2017;18(4):273-84.
5. Morse DR, O'Larnic J, Yesilsoy C. Apexification: review of the literature. *Quintessence Int*. 1990;21(7):589-98.
6. Ruaz R, Bashir MB, Anwar M, Rashid S, Ali S, Aliuddin AM. Efficacy of calcium hydroxide and mineral trioxide aggregate in the formation of Dentin Bridge-A randomized controlled trial. *Journal of the Pakistan Dental Association*. 2022;31(3).
7. Goel S, Nawal RR, Talwar S. Management of dens invaginatus type II associated with immature apex and large periradicular lesion using platelet-rich fibrin and biodentine. *Journal of Endodontics*. 2017;43(10):1750-5.
8. McGuinness, LA, Higgins, JPT. Risk-of-bias VISualization (robvis): An R package and Shiny web app for visualizing risk-of-bias assessments. *Res Syn Meth*. 2021; 12:55-61.
Available: <https://doi.org/10.1002/jrsm.1411>
9. Singh N, Mittal N, Baranwal HC, Tripathi R, Wang CK. Single-visit apexification in immature necrotic teeth using mineral trioxide aggregate as an apical plug: Case series. *SRM Journal of Research in Dental Sciences*. 2019;10(4):239-44.
10. Pavula, S.; Sherwood, I. Anand; Amaechi, Bennett Tochukwu1; Murugadoss, Vaanjay; Prakasam, Ernest Prince; Abirami, A. Azhagu. Cone-beam computed tomographic evaluation of biodentine apexification for traumatized necrotic immature permanent incisors: One-year clinical study. *Endodontology*. 2024;36 (1):67-74.
DOI: 10.4103/endo.endo_233_22
11. Conventional Multivisit calcium hydroxide apexification with rare apexogenesis like outcome and novel single visit MTA apexification followed by root reinforcement with fiber post: Two case reports. *Saudi Journal of Oral and Dental Research*.
DOI: 10.21276/sjodr.2017.2.2.1
12. Sridhar N, Tandon S. Continued root-growth and apexification using a calcium hydroxide and iodoform paste (Metapex®): Three case reports. *J Contemp Dent Pract*. 2010;11(5):63-70.
13. Bajwa NK, Jingarwar MM, Pathak A. Single visit apexification procedure of a traumatically injured tooth with a novel

- bioinductive material (Biodentine). International Journal of Clinical Pediatric Dentistry. 2015;8(1):58.
14. Bhandari S. Comparison of intracanal calcium hydroxide, mineral trioxide aggregate and portland cement to induce PH changes in simulated root resorption defects in human teeth-An *In vitro* study (Doctoral dissertation, Rajiv Gandhi University of Health Sciences (India)).
 15. Damle S, Bhattal H, Loomba A. Apexification of anterior teeth: a comparative evaluation of mineral trioxide aggregate and calcium hydroxide paste. Journal of Clinical Pediatric Dentistry. 2012;36(3):263-8.
 16. Nahar R, Chowdhury F, Alam MK. Apexification with the use of calcium hydroxide. Bangladesh Journal of Medical Science. 2012;11(2):143.
 17. Rafter M. Apexification: a review. Dent Traumatol. 2005;21(1):1-8. DOI: 10.1111/j.1600-9657.2004.00284.x. PMID: 15660748.
 18. Ham KA, Witherspoon DE, Gutmann JL, Ravindranath S, Gait TC, Opperman LA. Preliminary evaluation of BMP-2 expression and histological characteristics during apexification with calcium hydroxide and mineral trioxide aggregate. Journal of Endodontics. 2005;31(4): 275-9.
 19. Kumar A, Yadav A, Shetty N. One-step apexification using platelet rich fibrin matrix and mineral trioxide aggregate apical barrier. Indian Journal of Dental Research. 2014;25(6):809.
 20. Sharma S, Sharma V, Passi D, Srivastava D, Grover S, Dutta SR. Large periapical or cystic lesions in association with roots having open apices managed nonsurgically using 1-step apexification based on platelet-rich fibrin matrix and biodentine apical barrier: A case series. Journal of Endodontics. 2018;44(1):179-85.
 21. Ravi GR, Subramanyam RV. Calcium hydroxide-induced resorption of deciduous teeth: A possible explanation. Dental Hypotheses. 2012;3(3):90-4.
 22. Mathew, Josey & Syriac, Gibi & Nair, Manuja & Jayakumar, Rahul. Saudi journal of oral and dental research conventional multivisit calcium hydroxide apexification with rare apexogenesis like outcome and novel single visit MTA apexification followed by root reinforcement with fiber post: Two case reports. Saudi Journal of Oral and Dental Research. 2017;2:43-48. DOI: 10.21276/sjodr.2017.2.2.1
 23. Mathew, Josey, Syriac, Gibi, Nair, Manuja, Jayakumar, Rahul. Saudi Journal of Oral and Dental Research Conventional Multivisit Calcium Hydroxide Apexification with Rare Apexogenesis Like Outcome and Novel Single Visit MTA Apexification Followed by Root Reinforcement with Fiber Post: Two Case Reports. Saudi Journal of Oral and Dental Research. 2017;2: 43-48. DOI: 10.21276/sjodr.2017.2.2.1
 24. Tolibah YA, Kouchaji C, Lazkani T, Ahmad IA, Baghdadi ZD. Comparison of MTA versus Biodentine in Apexification Procedure for Nonvital Immature First Permanent Molars: A Randomized Clinical Trial. Children (Basel). 2022;14;9(3): 410. DOI: 10.3390/children9030410 PMID: 35327782. PMCID: PMC8946907.
 25. Aeran, Himanshu & Sharma, Mahema & Tuli, Avantika. (2021). Biodentine: Material of choice for apexification. International Journal of Oral Health Dentistry. 2021;7:54-56. DOI: 10.18231/j.ijohd.2021.011

© Copyright (2024): Author(s). The licensee is the journal publisher. This is an Open Access article distributed under the terms of the Creative Commons Attribution License (<http://creativecommons.org/licenses/by/4.0>), which permits unrestricted use, distribution, and reproduction in any medium, provided the original work is properly cited.

Peer-review history:
The peer review history for this paper can be accessed here:
<https://www.sdiarticle5.com/review-history/115528>