

## The long-term results of lingual mucosal grafts for repairing long anterior urethral strictures

Hussein Abdelhameed, Samir Elgamal, Mohamed A. Farha, Ahmed El-abd, Ahmed Tawfik & Mohamed Soliman

To cite this article: Hussein Abdelhameed, Samir Elgamal, Mohamed A. Farha, Ahmed El-abd, Ahmed Tawfik & Mohamed Soliman (2015) The long-term results of lingual mucosal grafts for repairing long anterior urethral strictures, Arab Journal of Urology, 13:2, 128-133, DOI: [10.1016/j.aju.2014.11.009](https://doi.org/10.1016/j.aju.2014.11.009)

To link to this article: <https://doi.org/10.1016/j.aju.2014.11.009>



© 2015 Arab Association of Urology



Published online: 05 Apr 2019.



Submit your article to this journal [↗](#)




Article views: 365



View related articles [↗](#)



View Crossmark data [↗](#)



ONCOLOGY/RECONSTRUCTION

ORIGINAL ARTICLE

# The long-term results of lingual mucosal grafts for repairing long anterior urethral strictures



Hussein Abdelhameed <sup>a,\*</sup>, Samir Elgamal <sup>b</sup>, Mohamed A. Farha <sup>b</sup>, Ahmed El-abd <sup>b</sup>,  
Ahmed Tawfik <sup>b</sup>, Mohamed Soliman <sup>b</sup>

<sup>a</sup> Fayoum Faculty of Medicine, Fayoum, Egypt

<sup>b</sup> Tanta Faculty of Medicine, Tanta, Egypt

Received 12 September 2014, Received in revised form 23 October 2014, Accepted 26 November 2014

Available online 7 February 2015

## KEYWORDS

Anterior urethral stricture;  
Graft;  
Buccal mucosa;  
Urethroplasty;  
Lingual mucosa

## ABBREVIATIONS

BMG, buccal mucosa graft;  
LMG, lingual mucosa graft;  
 $Q_{max}$ , maximum urinary flow rate

**Abstract Objective:** To evaluate the long-term results of repairing long anterior urethral strictures with lingual mucosa onlay grafts.

**Patients and methods:** This study included 23 patients (mean age 36.3 years, range 21–62) who had a lingual mucosa onlay graft for managing a long anterior urethral stricture, and who were followed up for  $\geq 5$  years. The mean length of the stricture was 4.6 cm. The International Prostate Symptom Score and uroflowmetry values were obtained before surgery, and at 3, 6 and 12 months afterwards, and annually thereafter. A retrograde urethrogram with a voiding cysto-urethrogram was taken before surgery, at catheter removal, after 3 and 6 months, and selectively thereafter.

**Results:** The mean (range) follow-up was 66 (60–72) months. The cause of the stricture was trauma in nine patients, instrumentation in seven, idiopathic in four, urethritis in two and previous hypospadias repair in one. The surgery was successful in 20 of the 23 patients (87%), and a recurrent stricture developed in the remaining three. There were no fistulae or clinically perceptible graft sacculations, and no long-term donor-site complications.

**Conclusions:** With a long-term follow-up, our series confirms the durability of lingual mucosal onlay grafts for treating long anterior urethral strictures. This

\* Corresponding author at: Fayoum Faculty of Medicine, Kimm Fares, 63514 Fayoum, Egypt. Tel.: +20 1005168856; fax: +20 084 6302350.

E-mail address: [aldaqados@yahoo.com](mailto:aldaqados@yahoo.com) (H. Abdelhameed).

Peer review under responsibility of Arab Association of Urology.



Production and hosting by Elsevier

procedure results in a long-term high success rate with few of the complications that occur primarily during the first year.

© 2015 Arab Association of Urology. Production and hosting by Elsevier B.V. This is an open access article under the CC BY-NC-ND license (<http://creativecommons.org/licenses/by-nc-nd/4.0/>).

## Introduction

There are many surgical options for the repair of a urethral stricture and the choice is based on the stricture site, length, and the degree of spongiofibrosis. Bulbar urethral strictures <2 cm long are repaired by excision of the fibrotic segment, with end-to-end anastomosis of the healthy ends of the urethra, and the long-term results are good. Substitution urethroplasty is required to repair longer (>2 cm) urethral strictures, anterior strictures and multiple urethral strictures [1].

Currently the buccal mucosa graft (BMG) is the most popular choice for substitution urethroplasty, with a high success rate. It has also been used to repair complex hypospadias [2]. Although the use of the BMG to repair a urethral stricture was first reported by Humby in 1941 [3], the present widespread use has been attributed to reports by Burger et al. [4] and Dessanti et al. [5] in 1992. The BMG is characterised by a thick epithelium, thin lamina propria and a rich blood supply facilitating early inosculation. Other advantages of the BMG are resistance to infection, ease of harvest, no hair and a hidden donor site.

Simonato et al. [6] first reported the use of lingual mucosa as a substitution tissue for graft urethroplasty, with good results. Subsequent studies of the lingual mucosa graft (LMG) to repair urethral strictures reported good outcomes. These series were based on a short- and medium-term follow-up. To our knowledge there are no studies evaluating the long-term results of LMG urethroplasty. Thus in the present study we specifically evaluated the results and complications of LMG urethroplasty over an extended follow-up period.

## Patients and methods

The study included 23 patients (mean age 36.3 years, range 21–62) who had a long anterior urethral stricture that was repaired between April 2006 and October 2007, using an onlay LMG technique. All patients were evaluated by a history, clinical examination, urine analysis and culture, uroflowmetry, retrograde urethrography and voiding cysto-urethrography. Patients were excluded if they had a short stricture (<2 cm) or a history of oral pathology or surgery. We verified that the study was conducted according to the requirements of World Medical Association Declaration of Helsinki (1964) and further recommendations.

The repair was carried out by two teams, one exposing the stricture and the other harvesting the lingual

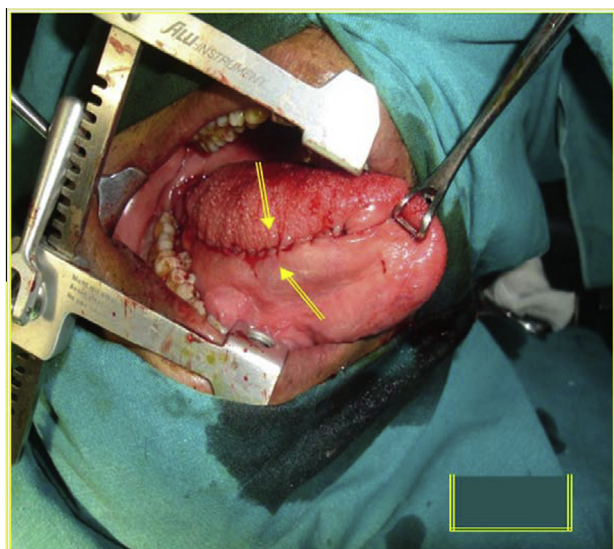
mucosa. Povidone-iodine oral rinses were used by the patients 2 days before surgery and continued for 6 days afterwards. The urethroplasty was performed under general anaesthesia with nasotracheal intubation. The patients with bulbar strictures were placed in the lithotomy position, while those with penile strictures were laid supine.

### Harvesting the LMGs

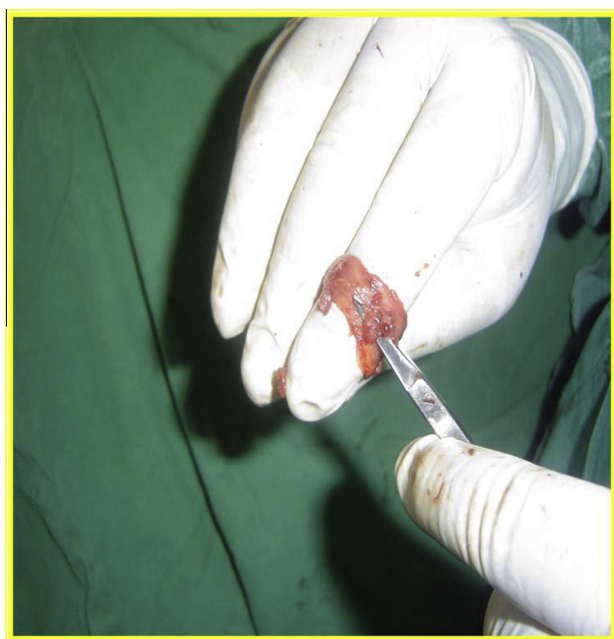
A mouth opener was used and the tongue was pulled outside the mouth with a Babcock clamp, exposing the tongue's ventrolateral surface. The site of the graft was from ventral to lateral mucosa of the tongue. Initially the graft was marked with a surgical pen, with care to avoid injury to the opening of the submandibular duct (Wharton duct) at the base of the tongue on the side of the frenum linguae. We infiltrated the graft site with normal saline and 0.01% adrenaline. We incised the graft edges with a scalpel and a full-thickness mucosal graft was harvested using scissors (Fig. 1). The graft bed was carefully examined for bleeding and closed using polyglactin 3–0 running sutures (Fig. 2). The graft

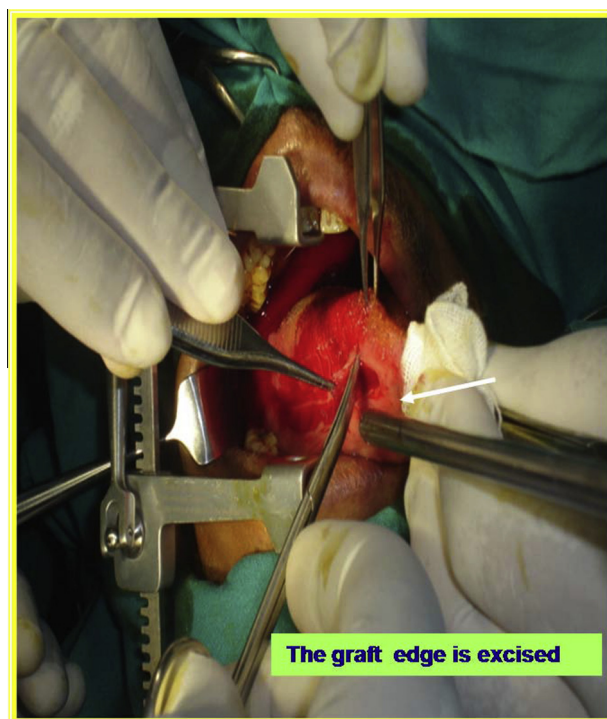

Figure 1 Excision of the graft edge.



**Figure 2** Closure of the LMG donor site.



**Figure 3** De-fattening of the LMG.

was de-fatted to remove all submucosal tissues (Fig. 3). When needed, the graft was harvested bilaterally.

#### Urethroplasty

A midline perineal incision was used in patients with bulbar strictures and a subcoronal circumferential incision was used in those with penile strictures, with degloving of the penis. Urethroplasty was performed using a ventral onlay technique in eight patients (five had a proximal bulbar stricture, two were obese, and one had a previous dorsal onlay urethroplasty) and dor-

sal onlay (Barbagli) technique [7] in the remaining 15. In the ventral onlay technique, the strictured urethra was incised ventrally, extending the incision distally and proximally into the normal urethra. The LMG was sutured to the urethral mucosa with continuous sutures of 4/0 polyglactin over a 16-F silicone catheter. The corpus spongiosum was closed to cover and support the LMG graft. In the dorsal onlay (Barbagli) technique the corpus spongiosum was dissected from the corpora cavernosa and rotated. The stricture site was incised dorsally, with extension of the incision proximally and distally into the healthy urethra. The LMG was spread-fixed to the corpora cavernosa. We added several quilting sutures to the graft, and made small incisions in the graft to avoid haematoma. A 16-F silicone catheter was introduced and the edges of the incised urethra were sutured both to the graft and to the corpora cavernosa.

#### Postoperative care and follow-up

Ceftriaxone 1 g was administered parenterally for 7 days, followed by an oral antibiotic until the urethral catheter was removed. Initially, a liquid diet is recommended, and then a soft diet before a regular diet was allowed. The IPSS and uroflowmetry values were obtained before surgery, at 3, 6 and 12 months afterwards, and annually thereafter. A retrograde urethrogram with a voiding cysto-urethrogram was taken before surgery, at catheter removal, after 3 and 6 months, and selectively thereafter. A successful outcome was defined as normal voiding, with no stricture apparent on the urethrogram, and no need for subsequent instrumentation.

For the statistical analysis a paired *t*-test was used for quantitative parametric data and a simple descriptive analysis as numbers and percentages for qualitative data.

#### Results

The underlying cause of the strictures, the stricture site, the mean stricture length (based on intraoperative measurements), previous treatments and presentation are shown in Table 1. One patient had extravasation during the pericatheter urethrogram taken at 3 weeks after surgery, and this was managed by an additional week of catheterisation. After LMG urethroplasty the maximum urinary flow rate ( $Q_{max}$ ) and IPSS improved significantly ( $P < 0.001$ ). This improvement was stable at all stages of the study over the 5-year period (Table 2).

Four patients (17%) had a wound infection that was managed successfully with a change in the antibiotics according to a culture-sensitivity test based on a wound swab. Three patients (13%) had bothersome postvoid dribbling, that was managed conservatively by manual

**Table 1** The patients' demographics.

Characteristic	Mean (range) or <i>n</i> (%)
Age (years)	36.3 (21–62)
Cause of the stricture	
Trauma	9 (39)
Iatrogenic	7 (30)
Idiopathic	4 (17)
Inflammatory	2 (9)
Failed hypospadias repair	1 (4)
Site of stricture	
Penile	6 (26)
Bulbar	12 (52)
Bulbopenile	5 (22)
Mean (range) stricture length (cm)	4.6 (3–11.5)
Previous stricture repair	
Internal urethrotomy	17 (74)
Urethroplasty	2 (9)
Presentation	
Weak stream	15 (65)
Dysuria	4 (17)
Suprapubic catheter	3 (13)
Chronic retention	1 (4)

**Table 2** The improvement in  $Q_{\max}$  and the IPSS.

Assessment	Mean (SD)	
	$Q_{\max}$ (mL/s)	IPSS
Before surgery	6.5 (3.8)	23 (5)
After		
1 year	21.5 (9)	6 (3)
2 years	20.4 (10.6)	5.5 (3.5)
3 years	20.2 (13.8)	4.8 (3.2)
4 years	21 (9)	4.3 (2.3)
5 years	19.3 (14.1)	5.4 (3.4)
<i>P</i>	<0.001	<0.001

urethral compression. After surgery, no patients had chordee, incontinence, or de novo erectile dysfunction. The complications were categorised according to the modified Clavien–Dindo system (Table 3).

The mean (range) length of the LMG was 5.6 (4–12) cm and the width was 1.5–2 cm. The graft was harvested unilaterally in 19 patients (83%) and bilaterally in four (17%). No major complications were reported at the donor site, but all the patients had mild oral discomfort in the first 4 days after harvesting. The patients were

able to ingest oral fluid within 24 h, soft solid food within 72 h, and a normal diet after a week. Tongue movement and talking was difficult in the first 2 days. Nine patients (39%) had oral numbness during the first 3 months (Table 3).

The mean (range) follow-up was 66 (60–72) months, and one patient was lost to follow-up. The urethroplasty was successful (i.e., no auxiliary procedures such as dilatation or internal urethrotomy, were required, and the  $Q_{\max}$  was > 12 mL/s) in 20 of 23 patients (87%). Retrograde urethrography showed a patent urethra with adequate calibre and no significant contracture or sacculation at the graft site. Recurrent strictures developed in three patients, and they presented with a diminished urinary flow ( $Q_{\max}$  < 12 mL/s) and dysuria. All failures occurred within the first year. One patient with recurrence had a past history of four optical urethrotomies with resultant marked spongiosfibrosis. One of the patients in whom the procedure failed was lost to follow-up but others were managed successfully by internal urethrotomy.

## Discussion

Substitution urethroplasty is indicated for long or complex urethral strictures, and a wide variety of techniques and tissues have been used for urethral repair. Currently the BMG is considered the best for urethroplasty, as noted above [8,9].

Recently the LMG has been used for urethral repair, with favourable outcomes comparable to those with a BMG. Simonato et al. [6] first reported the use of the LMG for substitution urethroplasty, treating eight patients with urethral strictures using a LMG in a one-stage dorsal onlay urethroplasty, and reported success in seven within a mean follow-up of 18 months. In 2008, Simonato et al. [10] reported another series of LMG urethroplasty, with a 21% recurrence rate within a mean of 17.7 months of follow-up. LMG urethroplasty was used by Barbagli et al. [11] for managing 10 patients with a urethral stricture, and only one patient developed a recurrence during the follow-up (mean 5 months). Xu et al. [12] corrected long segmented anterior urethral strictures in 25 patients using a combined

**Table 3** The categorisation of complications according to the modified Clavien–Dindo system.

Grade	Complications	<i>n</i> (%)	Management
I	Extravasation	1 (4)	Extended catheterisation
	Bothersome postvoid dribbling	3 (13)	
	Mild oral discomfort	23 (100)	Manual urethral compression
	Oral numbness	9 (39)	
II	Wound infection	4 (17)	Antibiotic according to culture sensitivity
III	Recurrent strictures	3 (13)	Internal urethrotomy in 2. Remaining 1 lost to follow-up
IV	No life-threatening		
V	No deaths		

double BMG, double BMG, and combined LMG and BMG. They reported that the combined oral mucosal graft is effective for long segmented anterior urethral strictures.

The lingual and the buccal mucosa arise from the same embryological origin, and both have a similar structure. The lingual mucosa is characterised by easy harvesting, good immunological characteristics (resistant to infection), a thick epithelium, a thin lamina propria, and many elastic fibres, with a rich blood supply. Such characteristics facilitate the uptake of the graft (imbibition and inosculation) [6,11].

Lingual mucosa is harvested from the ventrolateral surface of the tongue, providing a wide graft up to 5–8 cm long. Accordingly, a LMG can be used for urethral strictures of <6 cm long. For long strictures dual LMG strips can be used or combined with a BMG [10,13].

Although the BMG is the most popular graft for urethral repair, some have reported that harvesting the BMG is associated with donor-site complications. These include peri-oral paraesthesia, difficulty in opening the mouth due to scar contracture, and Stensen's duct injury [7,8]. However, Barbagli et al. [14], in a recent retrospective study, reported that BMG harvesting is safe and associated with minimal short- and long-term morbidity. The published series on LMG urethroplasty report minor donor-site complications soon after harvesting, such as slight oral discomfort, with no long-term complications. Asaduzzaman et al. [15], in a study focusing on the evaluation of the donor site after LMG harvesting, reported that donor-site complications are minor, immediate and with no long-term complications.

After LMG urethroplasty was first described by Simonato et al. [6] subsequent series have reported excellent outcomes after a short- and medium-term follow-up (Table 4) [6,10,11,16,17]. The present study specifically evaluated the outcomes of LMG urethroplasty over a prolonged follow-up. The favourable early outcomes remained stable during the extended follow-up, with three of the 23 patients developing a recurrence within the first year (two during the first 3 months, and one after 10 months). The significant ( $P < 0.001$ ) improvement in  $Q_{\max}$  and IPSS was stable during the 5-year follow-up in 20 patients (87%).

The LMG is associated with minor oral morbidity. Kumar et al. [18] reported tongue numbness in 6% of

their patients and all patients were pain-free within 6 days after surgery. The rate of temporary slurred speech was higher when the grafts were harvested bilaterally. Xu et al. [12] reported minimal donor-site complications, such as oral discomfort and a slight difficulty in the tongue movement, within the first 3 days after harvesting. The long-term complications, such as difficulty in opening the mouth and salivary changes, were minimal [6]. In accordance with previous series evaluating LMG urethroplasty, the donor-site complications in the present study were minor, e.g., difficulty in talking and oral numbness in nine patients during the first 3 months.

In conclusion, with a long-term follow-up, the present series confirms the durability of onlay LMGs for treating long anterior urethral strictures. This procedure results in a long-term high success rate, with few complications that occur primarily during the first year.

### Conflict of interest

None.

### Source of funding

None.

### References

- [1] Berglund RK, Angermeier KW. Combined buccal mucosa graft and genital skin flap for reconstruction of extensive anterior urethral strictures. *Urology* 2006;**68**:707–10.
- [2] Wessells H, Morey AF, McAninch JW. Single stage reconstruction of complex anterior urethral strictures: combined tissue transfer techniques. *J Urol* 1997;**157**:1271–4.
- [3] Humby GA. A one-stage operation for hypospadias. *Br J Surg* 1941;**29**:84–92.
- [4] Burger RA, Muller SC, el-Damanhoury H, Tschakaloff A, Riedmiller H, Hohenfellner R. The buccal mucosal graft for urethral reconstruction: a preliminary report. *J Urol* 1992;**147**:662–4.
- [5] Dessanti A, Rigamonti W, Merulla V, Falchetti D, Caccia G. Autologous buccal mucosa graft for hypospadias repair: an initial report. *J Urol* 1992;**147**:1081–3.
- [6] Simonato A, Gregori A, Lissiani A, Galli S, Ottaviani F, Rossi R, et al. The tongue as an alternative donor site for graft urethroplasty: a pilot study. *J Urol* 2006;**175**:589–92.
- [7] Barbagli G, Selli C, Di Cello V, Mottola A. A one-stage dorsal free graft urethroplasty for bulbar urethral strictures. *Br J Urol* 1996;**78**:929–32.
- [8] Markiewicz MR, Lukose MA, Margarone JE, Barbagli G, Miller SK, Chuang SK. The oral mucosa graft: a systematic review. *J Urol* 2007;**178**:387–94.
- [9] Markiewicz MR, Margarone JE, Barbagli G, Scannapieco FA. Oral mucosa harvest: an overview of anatomic and biologic considerations. *EAU-EBU Update Series* 2007;**5**:179–87.
- [10] Simonato A, Gregori A, Ambruosi C, Venzano F, Varca V, Romagnoli A, et al. Lingual mucosa graft urethroplasty for anterior urethral reconstruction. *Eur Urol* 2008;**54**:79–87.
- [11] Barbagli G, De Angelis M, Romano G, Ciabatti PG, Lazzeri M. The use of lingual mucosal graft in adult anterior urethroplasty: surgical steps and short-term outcome. *Eur Urol* 2008;**54**:671–6.

**Table 4** Previous clinical studies of LMG urethroplasty.

Refs.	n patients	Mean (range) follow-up (months)	Success rate, n/N or n (%)
[6]	8	22.1 (3–47)	5/8
[10]	29	17.7 (6–71)	79
[11]	10	5 (3–12)	9/10
[16]	30	9 (4–12)	83
[17]	34	8.6 (3–14)	88

- [12] Xu YM, Sa YL, Fu Q, Zhang J, Si JM, Liu ZS. Oral mucosal grafts urethroplasty for the treatment of long segmented anterior urethral strictures. *World J Urol* 2009;**27**:565–71.
- [13] Xu YM, Fu Q, Sa YL, Zhang J, Jin CR, Si JM, et al. Treatment of urethral strictures using lingual mucosa urethroplasty: experience of 92 cases. *Chin Med J* 2010;**123**:458–62.
- [14] Barbagli G, Fossati N, Sansalone S, Larcher A, Romano G, Dell'Acqua V, et al. Prediction of early and late complications after oral mucosal graft harvesting: Multivariable analysis from a cohort of 553 consecutive patients. *J Urol* 2014;**191**:688–93.
- [15] Asaduzzaman M, Quddus MR, Islam MS, Ahmed K, Rosy SK, Bhuiyan A. Donor site evaluation after lingual mucosal graft harvest for urethroplasty. *Bangladesh J Med Biochem* 2012;**5**:48–52.
- [16] Das SK, Kumar A, Sharma GK, Pandey AK, Bansal H, Trivedi S, et al. Lingual mucosal graft urethroplasty for anterior urethral strictures. *Urology* 2009;**73**:105–8.
- [17] Xu YM, Sa YL, Fu Q, et al. A preliminary report of lingual mucosa urethroplasty for the treatment of urethral strictures. *J Urol* 2008;**179**:15 (Abstract 39).
- [18] Kumar A, Goyal NK, Das SK, Trivedi S, Dwivedi US, Singh PB. Oral complications after lingual mucosal graft harvest for urethroplasty. *ANZ J Surg* 2007;**77**:970–3.