



Clinical Application and Evaluation of Specialised Ring Fixators for the Management of Upper and Lower Limb Bone Fractures in Dogs

**Rohit Kumar Sharma ^{a*}, Anil Kumar Bishnoi ^a,
Manu Prabh Sharma ^a and Praveen Bishnoi ^a**

^a *Department of Veterinary Surgery and Radiology, College of Veterinary and Animal Science, Rajasthan University of Veterinary and Animal Sciences, Bikaner, Rajasthan, India.*

Authors' contributions

This work was carried out in collaboration among all authors. All authors read and approved the final manuscript.

Article Information

DOI: 10.9734/JSRR/2024/v30i11829

Open Peer Review History:

This journal follows the Advanced Open Peer Review policy. Identity of the Reviewers, Editor(s) and additional Reviewers, peer review comments, different versions of the manuscript, comments of the editors, etc are available here: <https://www.sdiarticle5.com/review-history/112111>

Original Research Article

Received: 11/11/2023
Accepted: 15/01/2024
Published: 16/01/2024

ABSTRACT

Present study was conducted on nine-clinical cases of humerus (n=4), femur (n=3) and radius-ulna (n=2) fractures in dogs of either sex, weighing 5.5 to 18 kg. Both closed (n=6) and open (n=3) fractures were treated in this study. The fracture was reduced and stabilized by transfixation using modified ring fixators. Semicircular (n=4) and hybrid fixators (n=5) were used for upper limb and lower limb bones respectively. The main component of fixator i.e. aluminium rings were designed locally at Bikaner using 4-mm aluminium sheets and fabricated accordingly. Full rings were used for distal radial (n=2) and distal femoral (n=1) fractures whereas semicircular rings were made through cutting the full ring during surgery for specific humeral (n=4) and femoral (n=2) fractures. Specialised wire fixation bolt (iron based; weighing 5.5g) was also designed locally at Bikaner for

*Corresponding author: E-mail: drrhisharma3372@gmail.com, rohit27995sharma@gmail.com;

transcortical pin and ring articulation. Humeral and distal femoral fractures are challenging while bone plating of distal radial fracture demands further surgeries therefore external fixators were modified and applied in present study. Operated limbs were evaluated clinically with serial postoperative radiographs at regular intervals. Fixator-assembly evaluation and functional recovery of operated limbs were considered as objectives of this study.

Keywords: Ring fixators; lower limb; bone fractures.

1. INTRODUCTION

External skeletal fixators (ESF) are versatile technique [1] for fracture management [2]. Currently this technique became affordable [3] for pet owners [4] and hence can be used routinely [5] wherever required. Most common indication of ESF is open and severely infected fractures [6] especially in large or giant dog breeds [7] where other surgical technique is difficult to use successfully [8] and Bernarde *et al.*, [9]. Broadly ESF has been classified as linear, circular and hybrid technique [10] Aronsohn, [11] Heras-Jimenez *et al.*, [12] Beveer *et al.*, [13] Majority of ESF-technique [14] are usually applied to manage lower limb bone fractures in dogs [15] and Rao *et al.*, [16] and the main reason behind is ease of application [17] without much hindrance [18]. However linear fixtors can be used in any long bone [19] even with articulation with circular ring [20] and Cheong *et al.*, [21] but in previous literature there are restrictions for use of circular fixtors [22]. Circular fixtors are formed through articulation of various complete circular rings [23] and hence availability of huge amount of muscular or soft tissue around the upper limb bones limits its use [24]. Limited techniques are available [25]. for the management of compound or infected fractures [26] of humerus and femur in dogs [27]. Shape of bones [28] and arrangement of heavy musculature surrounding upper limb bones (i.e. femur and humerus) in dogs [27] are considered as major challenges [29] for placement of dense ESF-pins [30] and thereby complete assembly [27] and Yardımcı, *et al.*, [31]. Therefore present study was planned to evaluate the efficacy of modified circular fixation technique to overcome hurdles associated with use of complete circular fixators.

1.1 Objectives of Present Study

1. Application of fabricated external skeletal fixtors for upper and lower limb bone fractures and evaluation of their assembly.
2. Clinical and radiographic evaluation of limb function and bone health in postoperative

period after application of modified ring fixators

2. MATERIALS AND METHODS

Present study was conducted on nine clinical cases of dogs of different age, breed and sex referred to Department of Veterinary Surgery and Radiology, RAJUVAS, Bikaner. Evaluations of fabricated fixator's assembly along with evaluation of fracture healing (both clinical and radiographic evaluation) were decided as objectives of this study.

2.1 Pre-Operative Planning

Pre-operative clinical examination provided a tentative diagnosis of fracture and its location in all the nine cases. Essentially two-orthogonal radiographs were taken in all 9 cases of fractured limb. Clinical signs like status of weight bearing on the affected limb, soft tissue swelling, wounds (in compound fractures), pain and crepitus on palpation at the site of fracture were observed in all the nine cases According to Bilgili *et al.*, [14] Dwivedi *et al.*, [4] Dwivedi *et al.*, [32]. No neurological deficit was observed in any case. In all presented cases, animals were reported in either in recumbent position or in limping state; might be due to pain or immediate trauma shock. Neurological evaluation was performed in all the recumbent dogs to prevent surgical failure. Complete gross anatomy of affected bones was examined and safe corridors were determined for safe pin penetration according to previous studies [33,34]. Bilgili *et al.*, [14].

2.2 Specialised Ring Fixators and Surgical Procedure

All the cases were placed in lateral recumbency with lateral side towards surgeon. After clipping of hairs, fractured limb was prepared for aseptic surgery in all the cases. The dogs were pre-anaesthetized with a mixture of Inj. Xylazine @ 1 mg/kg and Atropine @ 0.04 mg/kg, intramuscularly. General anaesthesia was induced with a mixture of Inj. Ketamine Hcl @

5mg/Kg and Inj. Diazepam @ 0.5 mg/Kg, IV and was further maintained on Isoflurane in with 100% oxygen.

Techniques were modified and fixtor's assembly was fabricated into semicircular and hybrid ESF-systems Semicircular ESFs were applied over upper limb bone fractures whereas hybrid fixtors were applied for fixation of both upper and lower limb bone fractures (as done in previous studies viz. Yardimici *et al.*, [27] Rao *et al.*, [18] and Yardimici *et al.*, [31]. Details of various dimensions and design of implants used in this study were mentioned in Table.1.

In semicircular ring fixation and intramedullary pinning technique, single IM pin of diameter 40-60% of the bone isthmus was selected and driven into the fragments in retrograde fashion by using Jacobs pin chuck. In cases where open approach was adopted for femur, humerus, the standard surgical procedure was used for IM-pin insertion in open method for retrograde manner. After IM pin placement, 2 half end threaded pins were placed in proximal fragment at same plane but in different direction followed by attachment and fixation of proximal semicircular ring to same pins and secured with wire fixation bolt and nuts. Afterwards threaded connecting rods were inserted through the appropriate holes of proximally secured semicircular ring and then distal semicircular ring were secured with same threaded connecting rods. Wire fixation bolts were placed at appropriate holes in distal semicircular ring and then distal end threaded pins were inserted into the holes of wire fixation bolts of distal semicircular ring and drilled into the distal fragments as same as proximal pins. Before skin closure all the bolts and nuts including wire fixation bolts and nuts attached with threaded connecting rods were firmly secured and tightened. In few cases the IM-pin was left as tie-in combination with semicircular ESF. Details of rings used in present study in each cases were mentioned in Table 11.

In hybrid ESF technique, one complete circular ring was secured at the distal fragment through placement of 2 craniomedial and craniolateral full smooth pins and then ring was attached to smooth connecting bar of appropriate length followed by placement of 2 end threaded pins which were further attached to smooth connecting bar through stainless steel mini

clamps. Before tightening of assembly or implant, the fracture reduction was rechecked for proper anatomical alignment. Care was taken to ensure that the end threaded pins or schanz screw only penetrated the near skin and both cortices of bone without going further.

In all the cases assembly were fixed and clamps were positioned in such a way to allow adequate space for the post operative tissue swelling i.e., approximate 10 mm. Following this, the excess length of the transcortical pins and connecting bars were cut close to the assembly and mini-clamps in hybrid fixaors. Any skin tension around the transcortical pins was relieved by extending the stab incision. In cases where open reduction was performed, muscles and fascia were sutured in simple continuous pattern using braided Polyglactin 910 (Trusynth, SUTURES INDIA PVT. LTD., Bangalore) suture material. Skin incision was closed using braided silk (Trusilk, SUTURES INDIA PVT. LTD., Bangalore) in interrupted pattern.

2.3 Post-Operative Care

Following surgery, a sterile gauze pad, with 5% povidone iodine solution was wrapping around the transcortical pins and the same was applied over ESF construct to protect operative site. Then cotton padding was rolled and secured with bandage over the frame on the limb for external protection of ESF assembly. The surgical wound of transcortical pin insertion site and the transcortical pin at the skin and pin interphase were cleaned with 5% povidone iodine at the time of external bandage changing. Postoperatively, either Ceftriaxone (INTAS PHARMACEUTICAL LTD. Ahmedabad) @ 15-30 mg/kg body weight, i/m or cefpodoxime proxetil (INTAS PHARMACEUTICAL LTD. Ahmedabad) @ 5-10 mg/kg body weight, orally were used b.i.d for 5-10 days and Meloxicam @ 0.2- (INTAS PHARMACEUTICAL LTD. Ahmedabad) 0.5mg/kg body weight were administered intramuscularly o.d. for 3 days. Calcium-phosphorus and multi-vitamin preparation were added per oral in the post-operative period. Skin sutures were removed after 10-15 days of surgery.

The owners were instructed to restrict the movement of the dogs during fracture healing at least first three weeks postoperative. Subsequently, the dogs were allowed limited physical activities regularly.

Table 1. Details of implant used in construction and designing of ring fixtors

Dimensions of various items used in semi-circular and hybrid ESF construct			
S.No.	Name of Item		Dimensions
1.	Ring	Circular Semicircular	ID: 80 mm ID: 80mm ID: 120 mm
2.	Thickness of ring		3 mm
3.	Width of ring		15 mm
4.	Number of holes in each ring		32
5.	Width of each hole in a ring		5 mm
6.	Threaded connecting rod		Diameter: 4.5 mm Length: 75 mm
7.	K-wire		Diameter: 2 mm, 2.5 mm, 3 mm
8.	Metal used	Ring Threaded connecting rods and nuts Wire- fixation bolts	Aluminium Iron Iron

Physical examination of the affected limb during the follow up period was done to determine the wound healing status, wound infection, swelling, exudation, stability of the fixator, any mobility at fracture site, range of motion of joints above and below fractures and extent of weight bearing while walking and standing. The external skeletal fixation frame was checked in all the cases for implant failure, dismantling of implant, loosening of the transcortical pins and mini-clamps in hybrid ESF. Numbers of days required by the dog to start initial partial weight bearing on affected limb were also recorded. Limb function was evaluated on every follow up visit and also through regular telephonic contact with the owner. Lameness was graded based on amount of pain perception and amount of weight bearing on affected limb according to classification given by Larin *et al.* [35]. According to this classification grading has been done using numbers from 0 (excellent), 1 (very good) , 2 (good), 3 (fair), 4 (poor.) Once the fracture healing was evident on radiographic examination (bridging callus), and or clinical improvement of limb function noticed , the fixator was removed under xylazine sedation by cutting the transfixation pins at one side using a pin cutter and then the cut ends of the pins were cleaned and pulled using a plier. The pin tracts were cleaned and flushed using sterile saline solution containing povidone- iodine. The fixator was dismantled and cleaned for re-use of only that part, having capacity to further use or having no mechanical damage. In case of fixator instability in early post-operative period due to pin loosening, which led to instability of fracture

fragments or if the fixator caused wound to the adjacent soft tissues of the operated limb, the fixator was also removed. Bandage was applied to limbs after the apparatus was removed.

3. RESULTS AND DISCUSSION

In previous studies, the fabricated ring fixators were used successfully to treat acute or chronic fractures, open fractures with or without adjacent joint instability of upper and lower limb bone fractures Marcellin-little, [36] Bilgili *et al.*, [14] Yardimci *et al.*, [27] and Yardimci *et al.*, [31]. Presented study was planned to fill the lacuna of previous preliminary studies where aluminium based semicircular and hybrid fixtors were not applied especially for humeral and femoral fractures. Four cases were operated using semicircular ESF whereas five cases operated with hybrid ESF Table 2. If only semicircular rings without further attachments were used, then it was considered as semicircular while complete circular or semicircular rings with other attachments like LESF were used it was considered in HESF. Four humeral fractures were stabilised with semicircular fixtors whereas 2-cases of radius-ulna and three femur fractures were stabilised through hybrid fixtors. The fractures of radius-ulna and tibia are difficult to stabilize by internal fixation with intramedullary pinning as this technique may damage the joints associated with them Fossum, [3] Pope, [37] and Probst, [38]. Hence, to increase the stability of such fractures using newly modified fixtors, fabricated systems were applied in all the nine

cases of present research. Complete detailed findings of cases were available in Table 3. In post-operative follow-up period; most of the dogs seemed to tolerate the implant and started bearing weight, just next day to operation. The time from occurrence of fracture to its clinical reporting was 0 (C6), 1 (C2-C5), 4 (C1), 5 (C8), 6 (C7), 11 (C9) days whereas time from occurrence to fracture surgery was 2 (C5), 3 (C4), 4 (C2), 6 (C1), 8 (C7), 15 (C9), 21 (C3) days. The mean overriding of fracture fragments (%) calculated in present study through two orthogonal radiographs was $26.33 \pm 4.74\%$ which ranged from 10.44 – 48.83 in percentage. All the dogs used their extremities for walking within 1 to 9 days (average 2.33 days) of surgery. The mean time of surgery was noted as 145.33 ± 17.21 minutes, which ranged from 81-238 minutes. The implant was removed between 33 and 65 days (38.66 ± 5.91) after the surgery. Average diameter of transcortical pins used in whole study were 2.5 ± 0.08 mm (proximal fragments) and 2.57 ± 0.09 mm (in distal fragments). Repeated Pin size is one of the factors influencing the strength and stiffness of the fixator and its ability to resist the axial loading, bending and rotation associated with the weight bearing of the animal [3]. Fragomen and Rozbruch [39] described biomechanics of wires and half pins used in circular external skeletal fixation system. They stated that wire stability increases with increasing wire diameter and increasing tension placed across the wire. Frame stability is enhanced by using more wires per ring, placing wires on opposite sides of ring, securing wires directly to the ring, and inserting wires in different planes. Krischner pins of 1.5 mm and 2.0 mm diameter has been used by Bilgili et al, [14] for CESF in tibia and radius-ulna fractures in dogs weighing between 10 to 55 Kg. In a retrospective study, Cappellari et al (2019) used mentioned the use of pin diameter approximately 25% of the diameter of the bone segment for treatment of antebrachial and crural septic non-union fractures in dogs

using CESF. Many researchers (Aron & Toombs, [24] Gasser et al., [40]. Egger, [41] Harari, [1] Palmer et al., [42] Chaudhari et al., [43]. and Dwivedi et al., [32] have recommended using pins of a maximum of 20% of the size of bone diameter. Average diameter of intramedullary pins used as supplementary device along with ESF in upperlimb bones was 3.87 ± 0.31 mm. Average gap between ring's inner margin and dog's skin was noted 18.52 ± 2.19 mm through radiographic measurement system. Marcellin-Little [36] a researcher, recommended 10 mm (1 cm) distance between skin and inner margins of rings for better stabilization. But in present study to prevent ring -skin friction trauma, gap was increased and also we observed that stability is still not hampered in almost cases. In a study of biomechanics of Ilizarov's system (Calhoun et al, 1991), researchers found that compression stiffness was increased by increasing bone compression which was further accomplished clinically through decreasing the distance between the two rings. In four cases of humeral fractures; where semicircular rings were applied; the average distance between 2-semicircular rings was noted 54 ± 3.89 mm (ranged from 44.47 – 66.29mm) whereas in rest of the cases of hybrid fixtors where more than one semicircle ring was applied (C1.,C3,C5,C6,C7) the distance was 51 ± 12.96 mm (ranged from 20.96 – 96.15). Implant stability and radiographic as well as clinical healing was not affected till the follow-up through distance between rings maintained in present study. In this research, transcortical pin loosening (100%), proximal pin migration (25%), post-operative implant dismantling (12.50%), pin-tract infection (37.50%), joint stiffness (50%), osteomyelitis (12.50%), pressure sore (12.50%), distal pin migration (25%), and maggot wound (12.50%) were observed as post-operative complications Table 7. In one case (C3) spontaneous dismantling of ESF construct was reported and it may seem to be due to over-activity of dog.

Table 2. Types of modified fixtors used according to case presented

Case no.	Type of ESF
C1	Hybrid ESF
C2	Semicircular ESF
C3	Hybrid ESF
C4	Semicircular ESF
C5	Hybrid ESF
C6	Hybrid ESF
C7	Hybrid ESF
C8	Semicircular ESF
C9	Semicircular ESF

Table 3. Detailed case presentation and related findings of this study

Case No.	Age	Sex	Body Weight (Kg)	Breed	Aetiology of fracture	Limb	Bone	Open or closed	Fracture location	Fracture type	Fixation method
C1	10Mts	M	10	Non-descript	Accident	RH	Femur	Closed	Distal 1/3 rd	Slight oblique	Open
C2	2yrs	F	12	Non-descript	Accident	RF	Humerus	Closed	Distal 1/3 rd	Transverse	Open
C3	2yrs	F	12	Non-descript	Accident	LH	Femur	Open	Distal 1/3 rd	Comminuted	Open
C4	1yrs	F	18	Non-descript	Accident	RF	Humerus	Closed	Distal 1/3 rd	Slight oblique	Open
C5	2Mts	M	7	Non-descript	Dog fight	RH	Femur	Closed	Distal 1/3 rd	Comminuted	Open
C6	2yrs	F	16	Non-descript	Accident	RF	Radius-ulna	Open	Mid-shaft	Transverse	Open
C7	7Mts	M	18	Non-descript	Fall	RF	Radius-ulna	Closed	Distal 1/3 rd	Slight oblique	Open
C8	3yrs	F	14	Non-descript	Dog fight	RF	Humerus	Closed	Mid-shaft	Slight oblique	Open
C9	8Mts	F	5.5	Non-descript	Accident	RF	Humerus	Open	Proximal 1/3 rd	Slight oblique	Open
Mean ± SE	16.33 ± 3.69 (in months)	M=3 F=6	12.50 ± 1.49 Kg	All were N.D.	Accident=6 Dog fight=2 Fall=1	RH=2 RF=6 LH=1	Femur=3 Humerus=4 Radius-ulna=2	Open=3 Closed=6	Proximal1/3 rd =1 Mid-shaft=2 Distal1/3 rd =6	Slight oblique=5 Transverse=2 Comminuted=2	Open=all 9 cases
Range	2-36 moths	-	5.5-18 Kg	-	-	-	-	-	-	-	-

N.D.=Nondescript, M=Male, F=Female, Mts=Months, RF=Rightforelimb, RH=Righthindlimb, LF=Leftforelimb, LH=lefthindlimb

Table 4. Configuration of ESF with number, type and diameter of applied transcortical pins

Case No.	Number and diameters of transcortical pins in Group-II						Diameter of IMP (mm)	
	Number of transcortical pins In proximal fragment		In distal fragment		Total transcortical pins	Diameters of transcortical pins		
	Smooth pins	End-threaded pins	Smooth pins	End-threaded pins		In proximal fragment (mm)		In distal fragment (mm)
C1	-	2	2	-	4	2, 2.5	2.5, 2.5	-
C2	-	2	2	-	4	2.5, 2.5, 2.5, 2.5	2.5, 2.5	4
C3	-	4	-	3	7	3, 3	3, 3, 3	-
C4	-	2	-	2	4	3, 3	3, 3	4
C5	-	2	-	3	5	2, 2, 2	1.5, 2	3
C6	-	3	2	-	5	2.5, 2.5, 2.5	2.5, 2.5	-
C7	1	1	2	-	4	2.5, 2.5	2.5, 2.5	-
C8	2	-	2	-	4	3, 3	3, 3	4.5
C9	1	1	1	1	4	1.5, 2.5	2, 2.5	-
Total	4	17	11	9	41	-	-	-
Mean ± SE	-	-	-	-	-	2.5 ± 0.08	2.57 ± 0.09	3.87 ± 0.31
Range	-	-	-	-	-	1.5-3	1.5-3	3-4.5

Table 5. Radiographic healing grade at regular post-operative intervals

Case No.	Radiographic healing grade			
	0-2 week	2-4 week	4-6 week	6-8 week
C1	4	3	2	1
C2	4	3	2	2
C3	4	3	2	2
C4	5	4	3	2
C5	4	3	3	3
C6	4	3	3	2
C7	2	1	1	1
C8	Dead	-	-	-
C9	4	3	2	2
Mean ± SE	3.87 ± 0.29	2.87 ± 0.29	2.25 ± 0.25	1.87 ± 0.22

Table 6. Radiographic healing progress (% cases) at regular post-operative intervals for limb bone fractures

Time interval (week)	Radiographic healing grade (% cases)				
	Grade 5	Grade 4	Grade 3	Grade 2	Grade 1
0-2 week	12.5%	75%	0%	12.5%	0%
2-4 week	0%	12.5%	75%	0%	12.5%
4-6 week	0%	0%	37.5%	50%	12.5%
6-8 week	0%	0%	12.5%	62.5%	25%

3.1 Radiographic Healing Status

Radiographic healing for each case was assessed up to 8th week and graded 1 to 5 according to Hammer et al, [44]. Grading description includes numbering from 1 to 5. Meaning reveals callus formation, fracture line visibility and stage of union. For example, 1 (homogenous bone structure, obliterated, achieved), 2 (massive callus with bone trabeculae crossing fracture line, barely discernible, achieved), 3 (apparent callus with visibility of fracture line, discernible, uncertain), 4 (trace callus with no bridging of fracture line, distinct, not achieved), 5 (no callus formation, distinct, not achieved). Table 5 presents radiographic healing grade at different interval for all the nine cases. The mean radiographic healing grade of all the 9 cases at 2nd, 4th, 6th and 8th week interval were 3.87 ± 0.29, 2.87 ± 0.29, 2.25 ± 0.25, 1.87 ± 0.22 respectively. Table 6 showing radiographic healing progress (in % cases) at regular post-operative intervals.

3.2 Wound Healing and Clinical Evaluation of Limb Function

In the present study, total all the nine cases (compound fracture=3; closed fracture=6) were treated by open method of fracture reduction. In post-operative follow-up it has been reported that

wound at the fracture site healed progressively with achieving complete healing from 2 to 3 weeks post fracture immobilization. Lameness grading was done (up to 6th week post operative period) with slight modification in the limb usage classification given by Larin et al. [35]. Larin et al., [35] made one hypothetical classification from 0 (excellent: no visible lameness), 1 (very good; intermittent mild weight bearing), 2 (good; intermittent non-weight bearing), 3 (fair; toe touching), 4 (poor; always non weight bearing) and used in their study. Details about lameness grading of this study are mentioned in Table 9 and Table 10 Post-operatively, at regular interval, the mean of lameness score was 2.75 ± 0.36; 2.5 ± 0.37; 2.12 ± 0.39; 1.87 ± 0.44; 1.55 ± 0.55; 1.25 ± 0.55; at 1st, 2nd, 3rd, 4th, 5th and 6th week respectively. Moreover, in later outcomes outcome, with the long time period of follow-up, the limb function was found excellent, good, fair and poor in 50%; 25%; 12.50% and 12.5% cases, respectively. Statistically (using student t-test), lameness scores at different intervals were non-significantly associated.

3.3 Trans-Cortical Pin Loosening and Implant Stability in Post-Operative Follow-up Period

The whole implant and transcortical pins maintained their position in a satisfactory manner

Table 7. Postoperative complications reported in this study

Complications	Postoperative complications		
	Early complication/Total noted cases	Late complication/Total noted cases	Total percentage(%)
Transcortical pin loosening	1/8	7/8	100%
Spontaneous Implant dismantling	-	1/8	12.50%
Ring bending	-	-	0%
Pin tract infection	-	3/8	37.50%
Slight joint stiffness	-	4/8	50%
Delayed-union	-	-	0%
Osteomyelitis	-	1/8	12.50%
Dragging of limb	-	-	0%
Angular deformity of limb	-	-	0%
Pressure sore due to pins	-	1/8	12.50%
Proximal IMP migration	1/4	-	25%
Distal IMP migration	-	1/4	25%
Shortening of limb	-	-	0%
Maggoted wound	-	1/8	12.50%

Table 8. Time period of transcortical pin loosening and ESF assembly removal

Case no.	Bone	No. of pins loosened in proximal fragment	Time of fragment loosening	proximal pin	No. of pins loosened in distal fragment	Time of fragment loosening	distal pin	Days of removal	ESF
C1	Femur	1 st -pin 2 nd -pin (out of 2 pins)	2 nd week 6 th week		-	-		41	
C2	Humerus	1 st pin (out of 2 pins)	3 rd week		-	-		34	
C3	Femur	-	-		All 3 pins of distal fragment	5 th week		33	
C4	Humerus	-	-		1 st -pin 2 nd -pin (out of 2 pins)	6 th week 7 th week		49	
C5	Femur	-	-		2 nd Pin (out of 3 pins)	3 rd week		40	
C6	Radius-ulna	1 st -pin 3 rd -pin (out of 3 pins)	6 th week 9 th week		-	-		65	
C7	Radius-ulna	-	-		-	-		35	
C8	Humerus	EARLY DEAD	-		-	-		-	
C9	Humerus	1 st -pin 2 nd -pin (Out of 2 pins)	3 rd week 8 th week		All 2 pins of distal fragment	8 th week		51	

Table 9. Lameness score (% cases) at weekly interval up to 6th week

Case No.	1 st bearing (days)	Pre-operative lameness grade	Grade of lameness up to 6 th post-operative week						Final outcome
			1 st week	2 nd week	3 rd week	4 th week	5 th week	6 th week	
SH1	1	4	2	2	2	1	1	1	Good
SH2	1	4	3	3	2	2	1	0	Excellent
SH3	1	4	3	3	3	4	4	4	Poor
SH4	1	4	3	3	3	2	2	2	Good
SH5	6	4	4	4	3	2	1	0	Excellent
SH6	1	4	2	1	1	1	0	0	Excellent
SH7	1	4	1	1	0	0	0	0	Excellent
SH8	Dead	4	-	-	-	-	-	-	-
SH9	9	4	4	3	3	3	3	3	Fair
Mean ± SE	2.33 ± 1.03	4 ± 0	2.44 ± 0.44	2.22 ± 0.43	1.89 ± 0.42	1.67 ± 0.44	1.33 ± 0.47	1.11 ± 0.51	-
Range	1-6	4	1-4	1-4	0-3	0-4	0-4	0-4	-

Table 10. Lameness score (% cases) at weekly interval up to 6th week

Time interval (week)	Lameness score (% cases)				
	Poor	Fair	Good	Very good	Excellent
1 st week	25%	37.50%	25%	12.50%	0%
2 nd week	12.5%	50%	12.5%	25%	0%
3 rd week	0%	50%	25%	12.50%	12.50%
4 th week	12.50%	12.50%	37.50%	25%	12.50%
5 th week	12.50%	12.50%	12.50%	37.5%	25%
6 th week	12.50%	12.50%	12.50%	12.50%	50%

Table 11. Details of rings (fabricated/ circular) used in present study

Case no.	Inner diameter	Type	Total	Fragment involve
C1	80	Complete	1	One in Distal
C2	120	Semicircle	2	proximal & distal
C3	120	Semicircle	2	Two in Proximal
C4	80	Semicircle	2	proximal & distal
C5	80	Semicircle	1	One in Distal
C6	80	Complete	1	One in Distal
C7	80	Complete	1	One in Distal
C8	80	Semicircle	2	proximal & distal
C9	80	Semicircle	2	proximal & distal
Mean± SE	88.89 ± 5.87	-	-	-
Range	80-120	-	-	-

throughout the healing period in 8 out of 9 cases. In all the nine cases of this study, semicircular and or hybrid ESF was applied and for these total 15 simple pins and 26 end-threaded pins were used. In these cases, 4 simple pins and 17 end-threaded pins were used in proximal fragments while 11 simple pins and 9 end-threaded pins were used in distal fragments. The whole ESF construct including proximal and distal fragment transcortical pins, was formed by 4 pins in 6 cases (66.67%), 5 pins in 2 cases (22.22%) and 7 pins in only one case (11.11%). In the proximal fragment, one simple transcortical pins was applied in 2 cases while 2 simple pins in one case only. In 8 cases, in the proximal fragment, 17 end-threaded transcortical pins were used. In the distal fractured fragment, 2 simple transcortical pins were used in 5 cases, while in one case, one simple and one was end-threaded pin were used. In distal fragment, 3 end-threaded pins were used in one case and 2 end-threaded pins were used in one another case. Hence, overall configuration of transcortical pins in the proximal and distal fragment was 2:2 in 6 cases (66.67%), 4:3 in 1 cases (11.11%), 2:3 in 1 case (11.11%) and 3:2 in 1 case (11.11%) (Table 4). However, one case (C3) has died out of nine cases. In one case of communitied distal femur fracture (C3) implant got dismantled in early phage of recovery. Refer Table. 8 for postoperative pin loosening

throughout the healing period. Pin design is an important parameter affecting bone fixation pin stability [45] Anderson *et al*, 1997 and Cross *et al.*, [46]. The number and size of pins or k-wires placed per segment should be selected based on the support required, including the load-sharing capability of the bone, the dimensions of each segment, and the weight of the animals Rovesti, [47]. Most of the frames were constructed as 2 semicircular with or without linear ESF attachments or complete circular rings with LESF. and were found providing good stability till removal except in one case (C3). Bilgili *et al*, [14] used 2 complete circular rings and 1 partial ring for 3 ring construct in their study for lower limb bones and found good stability. In our study, modifications and fabrications in the constructs were required as applied and evaluated by Yardimci *et al.*, [31] In a study, 6 cases of compound radius-ulna and tibia fractures were stabilized by aluminium based Ilizarov's ring fixator and all the 6 cases were stabilised with two full and one 5/8 th partial ring construct (Dwivedi *et al.*, [4]. Similarly in this study the ring material, aluminium was utilized for ESF construct. In all 9 cases, aluminium metal was preferred for circular rings. Similarly, Dwivedi *et al.*, [4] used aluminium circular rings for management of compound radius-ulna and tibia fractures in dogs. Bilgili *et al.* [14] used circular rings composed of ETAL-74 (94.5% aluminium,

1.5% magnesium, 4.5% copper) for the fixation of tibia and radius-ulna fractures in dogs. Yardemci *et al.*, [27] Yardemci *et al.*, [31] used semicircular rings made-up of carbon fibres and found good stability (because of light weight of rings) for management of upper limb bone fractures in dogs which were tolerated well throughout the healing period. Similarly in this study aluminium based fixtors (according to Dwivedi *et al.*, [4] were fabricated for management of humeral and femoral fractures to achieve better results. The mean period of initial partial weight bearing in all 8 cases (one case died after surgery) of the research was 2.33 ± 1.03 days and it ranged from 1 to 6 days. The early weight bearing avoids complications like bone and muscle atrophy. The major purpose of all fracture treatment methods is to obtain the soonest possible recovery Ferretti, [10] and early functional limb use Egger, [2]. Early limb use promotes fracture healing by allowing axial micromotion at the fracture site and also prevents inactivation atrophy in patients with bone fractures Yardimci et al, [31] Radke et al, [48] and Lincolan, [49] Post-operatively, at regular interval, for all cases the weight bearing status on the operated limbs improved progressively. In our present total cases of study, at 6th week of post-operative period 75 % cases (n=6 out of 8) were showing good to excellent weight bearing on the operated limb. Dwivedi *et al.*, [4] found that from 3rd post- operative week onward dogs started bearing weight on the operated leg with minimal limping and during the 8th week the dogs were able to bear full weight on both the forelimbs and hind limbs operated with CESF and were able to jump without evincing pain, except one dog, which did not show signs of bone healing. Langley-Hobbs (2003) found that immediate post-operative radiographic assessment helped in verification of the four 'A's like apposition, alignment, angulation and apparatus. In present study, of all the treated cases by sole ESF (C3, C6, C7, C9 i.e. fabricated ring fixators only), 3 cases in immediate postoperative radiographs were found with complete reduction with appropriate alignment of fractured fragments. In present study, pin tract infection (37.50%, n=3 out of 8 cases) was reported only in later post-operative period (Table: 7). Pin tract sepsis is caused by necrosis and infection of soft and osseous tissue around the pin. Excessive pin motion directly contributes to the infection. It is characterised by persistent and excessive purulent drainage associated with soft tissue inflammation and patient discomfort. Pin tract infection can be

minimized by reducing skin tension around the pin, avoiding the thermal necrosis of bone during pin insertion, and limiting pin bone and pin-skin motions Rovesti, [47] Piermattei *et al.*, [50] Harari, [1] and Johnson *et al.*, [51]. In one case (C4) out of nine cases, signs of osteomyelitis in the immobilized bone were noted radiographically. Clinically the limb was graded with good weight bearing score while radiographically fracture healing was graded fair up to 10th post-operative week as described earlier in results. Johnson *et al.*, [52]. treated 28 cases of dogs with radial and tibial bone fractures by the use of linear ESF. Radiographic signs of osteomyelitis were recognised in 12 bones and clinically in one dog only. As all the radiographic signs of osteomyelitis resolved including those in 9 dogs of Johnson's study not treated with antibiotics, it was hypothesized that the responses noted radiographically may have resulted from stimulation other than bacterial infection Young et al., [53]. The trauma of pin insertion, the stresses caused by early motion of the pins in the bone, and the healing response at the fracture site may be the other possible causes. To reduce the risk of osteomyelitis with ESF immobilization, the animal should be kept in a clean environment, the fixator should be protected with a sleeve of fabric to avoid external contamination and signs of swelling and redness should be effectively treated. In present study also, till the implant removal the construct was kept protected from external environment by bandaging whole assembly completely including the proximal and distal part of the limb. In a study Yardimci et al, [31] of semicircular external skeletal fixation and IM-pin tie-in combination, during post-operative radiographic examination, one case of humeral fracture was found with delayed union due to a large gap in between fracture fragments. However, in present study delayed union is not reported and all live cases recovered well (except C8, died) with few clinical complications. The large number of fractures reduced with less than anatomical results reflects the severity of fracture [53] and the frequent use of closed reduction Rovesti, 2016 [47] and Johnson *et al.*, [51]. Johnson *et al.*, [51]. repaired radial and tibial fractures in 28 dogs using ESF and in their study they noted valgus or rotational mal-alignment in 16 dogs. Though the angular deformities were visually evident [54] no effect was noted on function of limb. Fortunately angular deformities were not evident in present research throughout the study period.

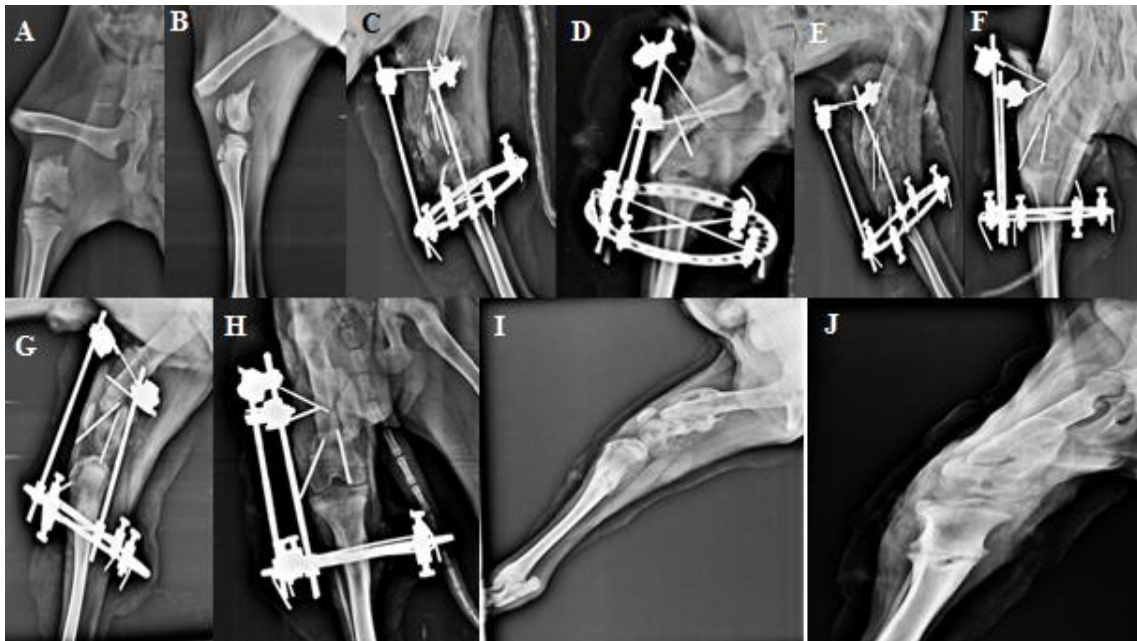


Fig. 1, Radiographs of Case- no.1: Preoperative (A&B), Immediate post-operative (C&D), 2nd – week post-operative (E&F) , 4th –week postoperative (G&H), 6th – week post-operative (I&J)

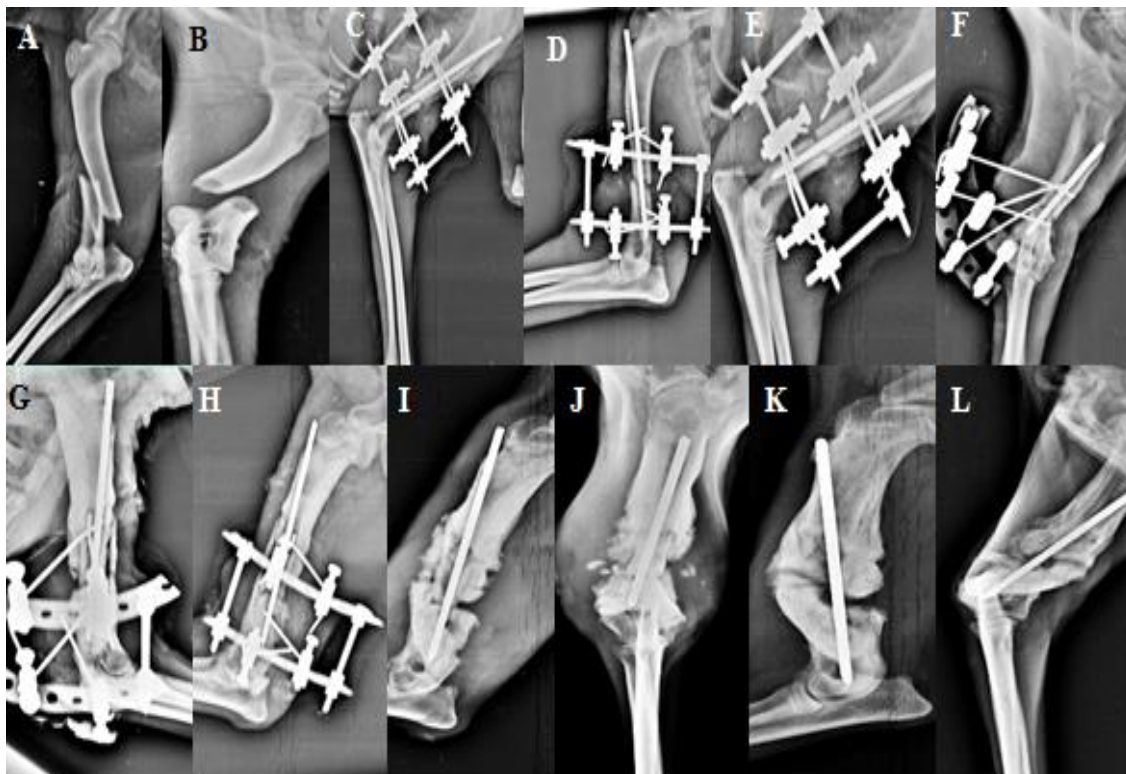


Fig. 2, Radiographs of Case- no.2: Preoperative (A&B), Immediate post-operative (C&D), 2nd – week post-operative (E&F) , 4th –week postoperative (G&H), 6th – week post-operative (I&J), 8th-week post-operative (K&L)

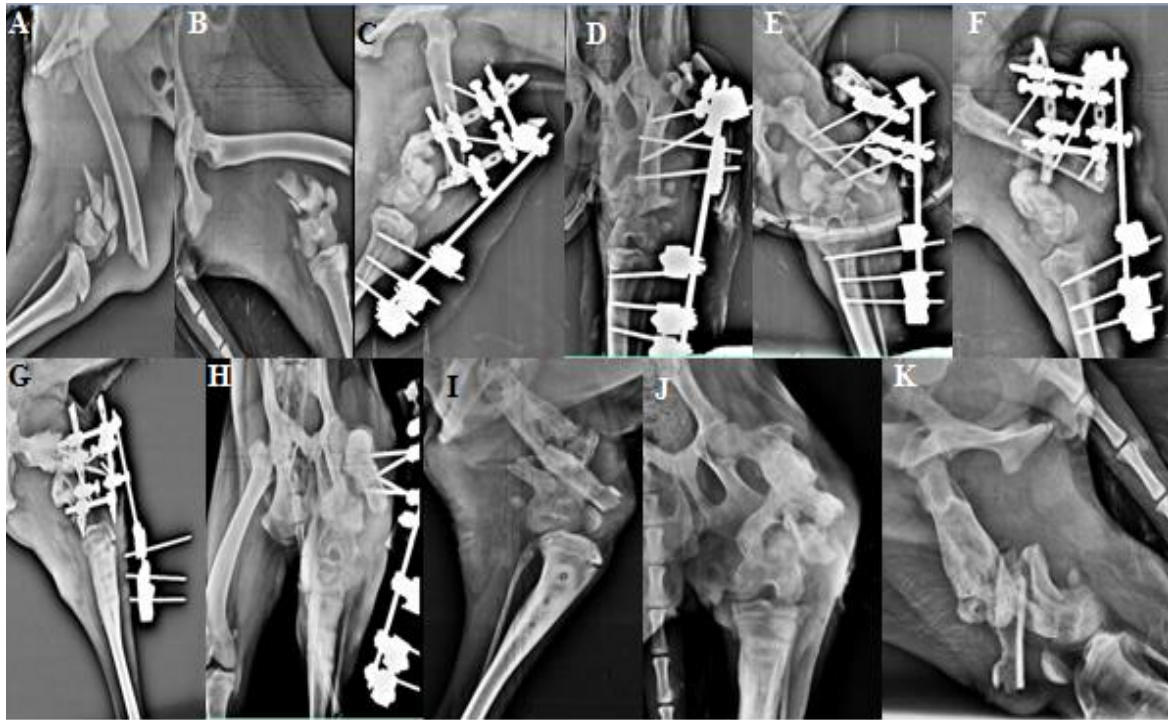


Fig. 3, Radiographs of Case- no.3: Preoperative (A&B), Immediate post-operative (C&D), 2nd – week post-operative (E&F) , 4th –week postoperative (G&H), 8th – week post-operative (I&J), 16th-week post-operative (K)

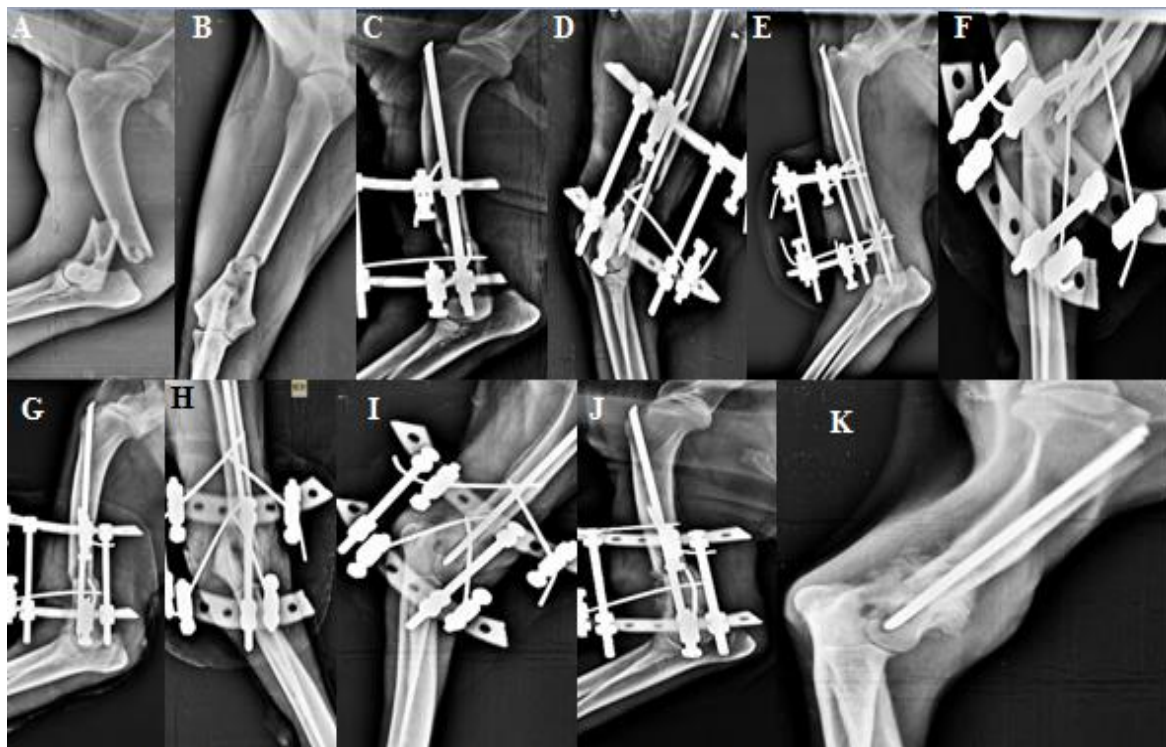


Fig. 4, Radiographs of Case- no.4: Preoperative (A&B), Immediate post-operative (C&D), 2nd – week post-operative (E&F) , 4th –week postoperative (G&H), 6th – week post-operative (I&J), 13th-week post-operative (K)

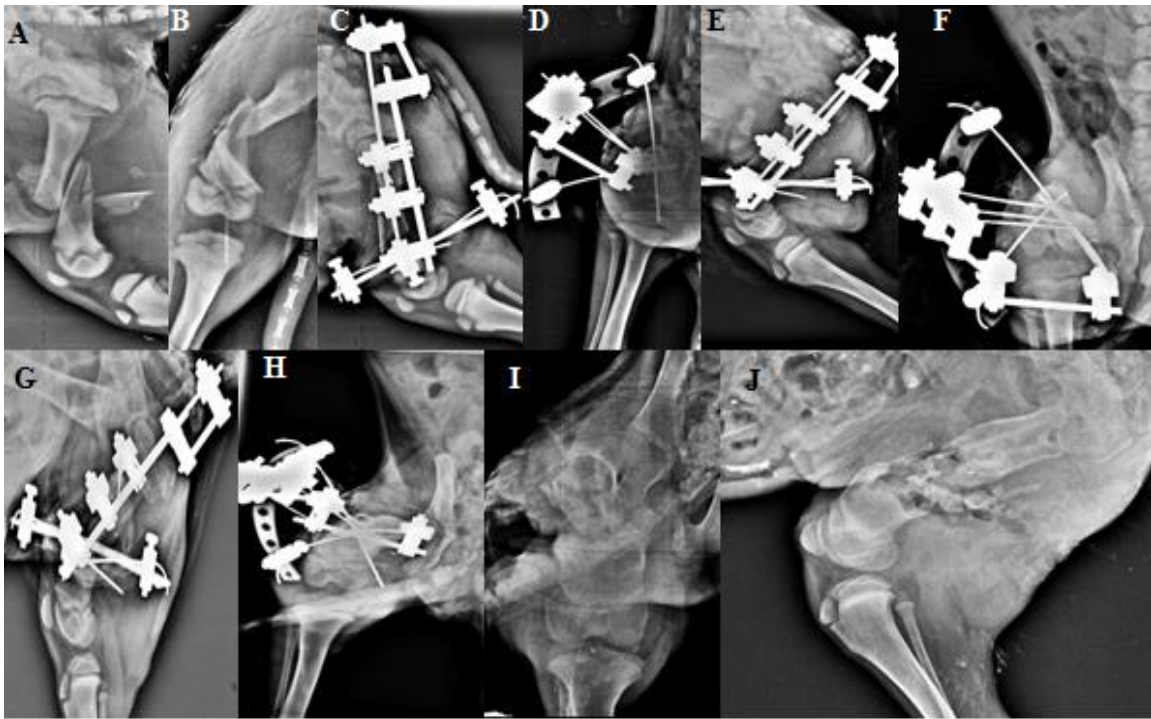


Fig. 5, Radiographs of Case- no.5: Preoperative (A&B), Immediate post-operative (C&D), 2nd – week post-operative (E&F) , 4th –week postoperative (G&H), 8th – week post-operative (I&J)

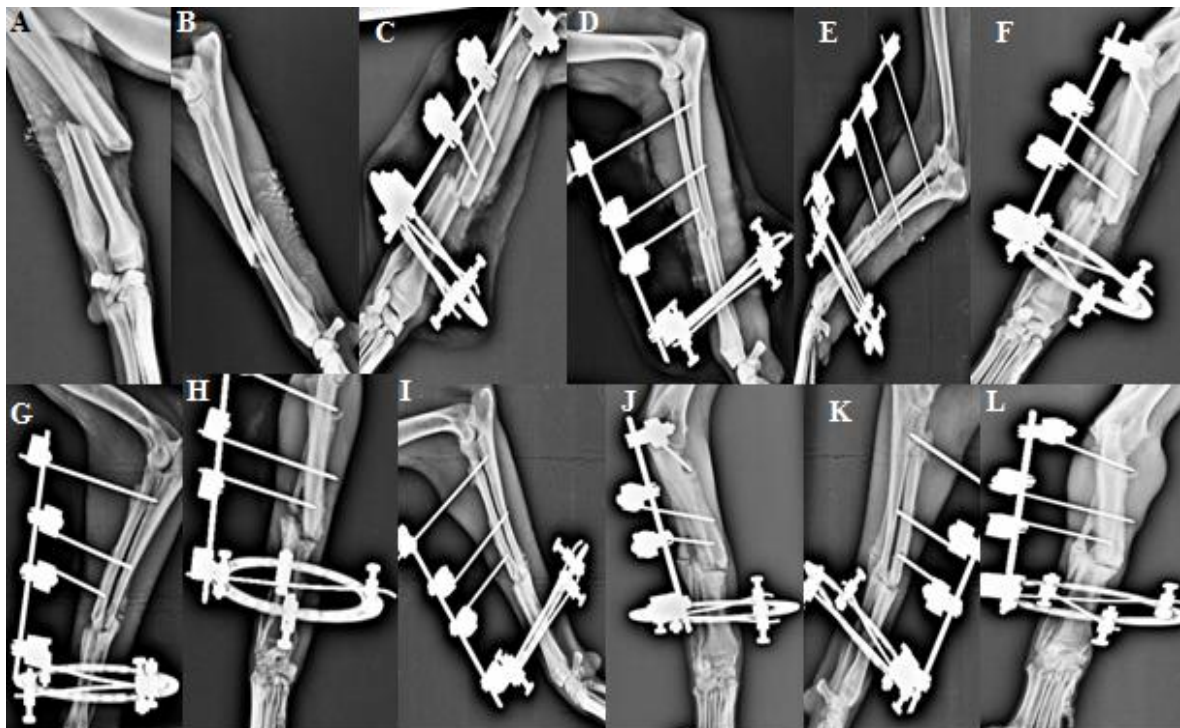


Fig. 6, Radiographs of Case- no.6: Preoperative (A&B), Immediate post-operative (C&D), 2nd – week post-operative (E&F) , 4th –week postoperative (G&H), 6th – week post-operative (I&J), 8th – week post-operative (K&L)

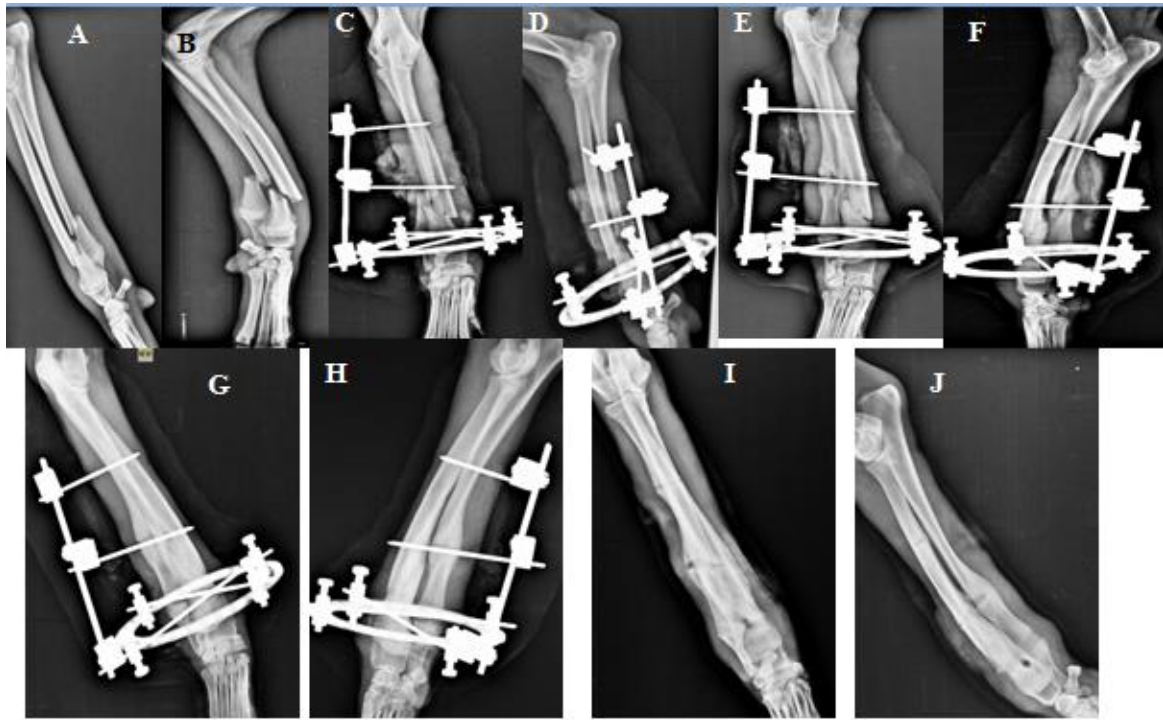

Fig. 7, Radiographs of Case- no.7: Preoperative (A&B), Immediate post-operative (C&D), 2nd – week post-operative (E&F) , 4th –week postoperative (G&H), 9th – week post-operative (I&J)

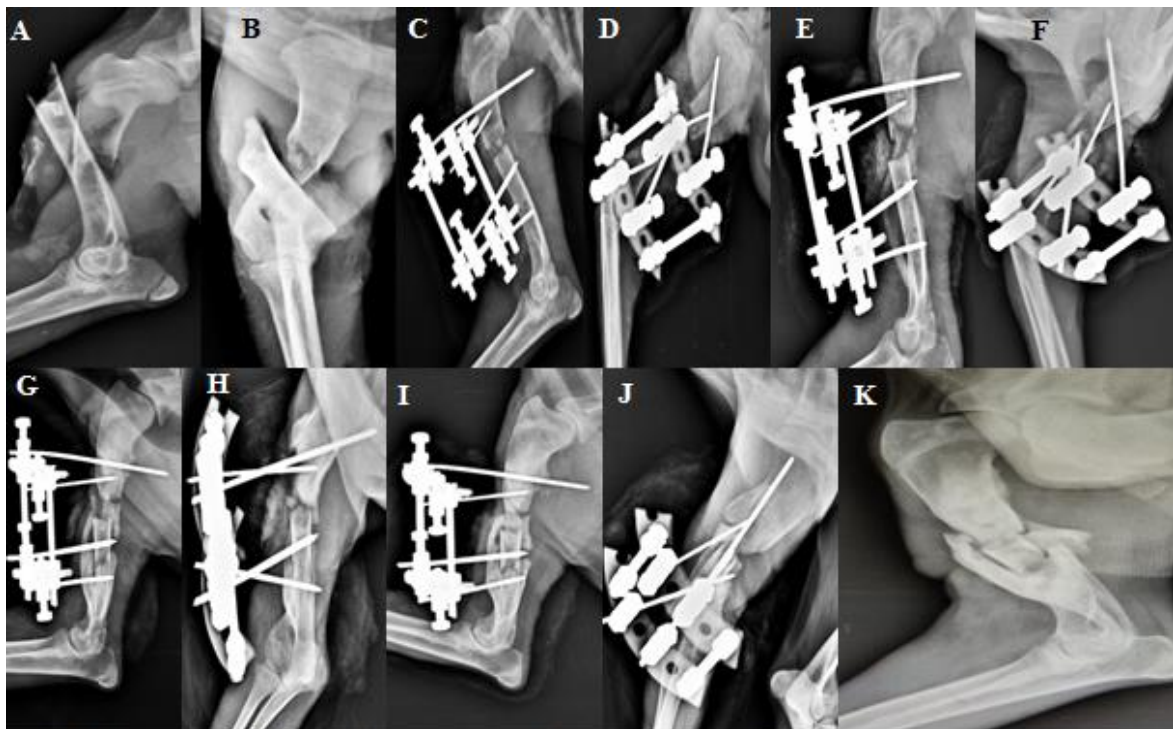


Fig. 8, Radiographs of Case- no.9: Preoperative (A&B), Immediate post-operative (C&D), 2nd – week post-operative (E&F) , 4th –week postoperative (G&H), 6th – week post-operative (I&J), 8th – week post-operative

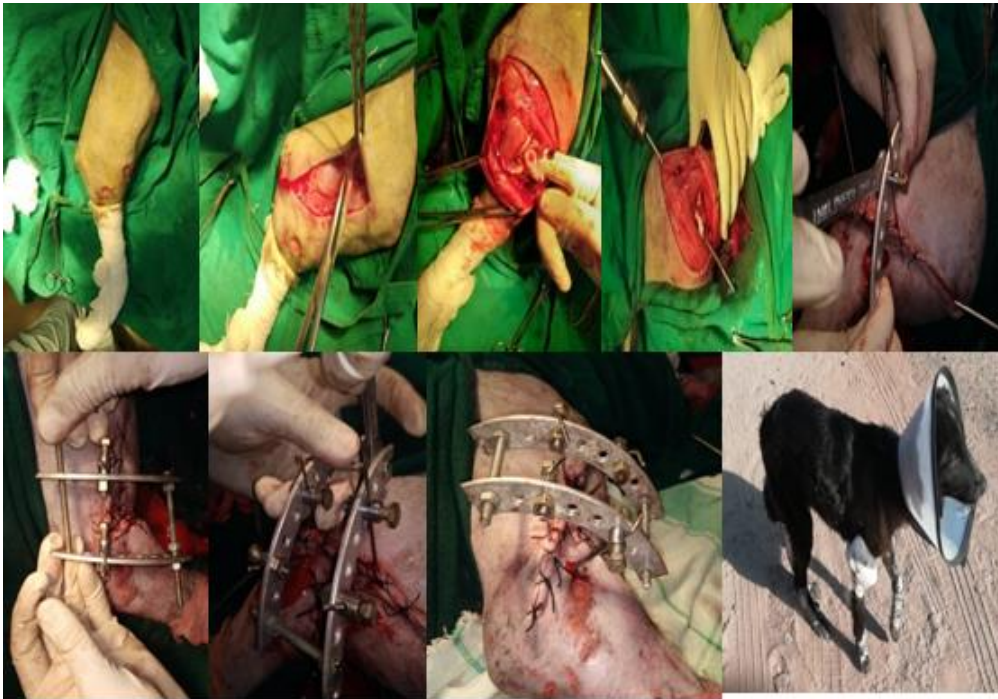

Fig. 9 Fixation of humeral fracture using semicircular external skeletal fixation system assembly

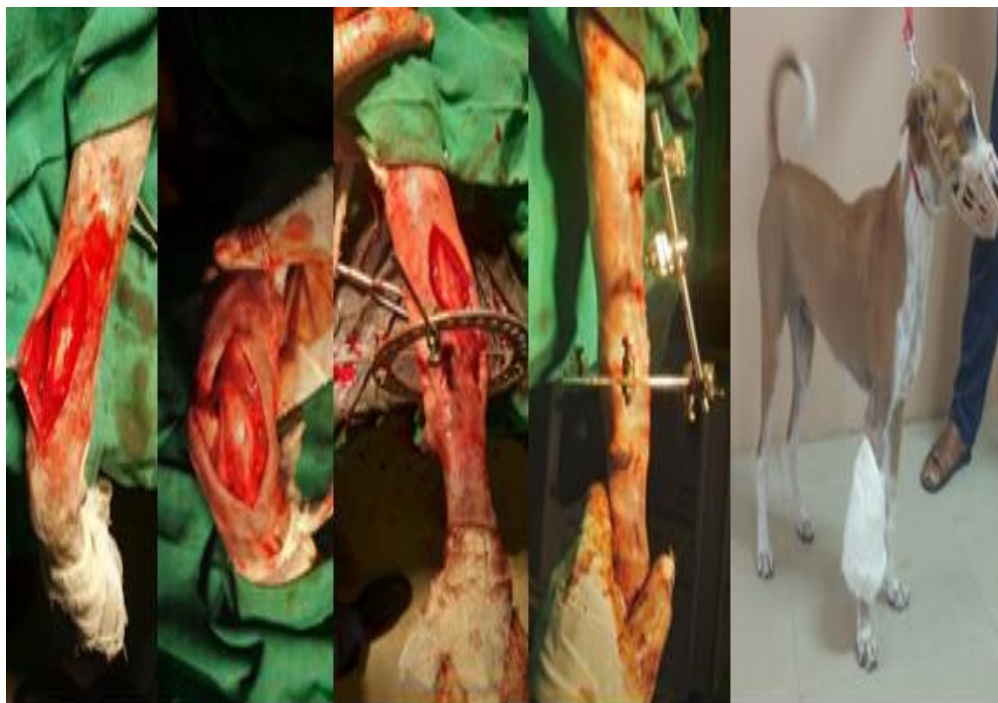

Fig. 10 Fixation of distal radius-ulna fracture using hybrid external skeletal fixation system assembly

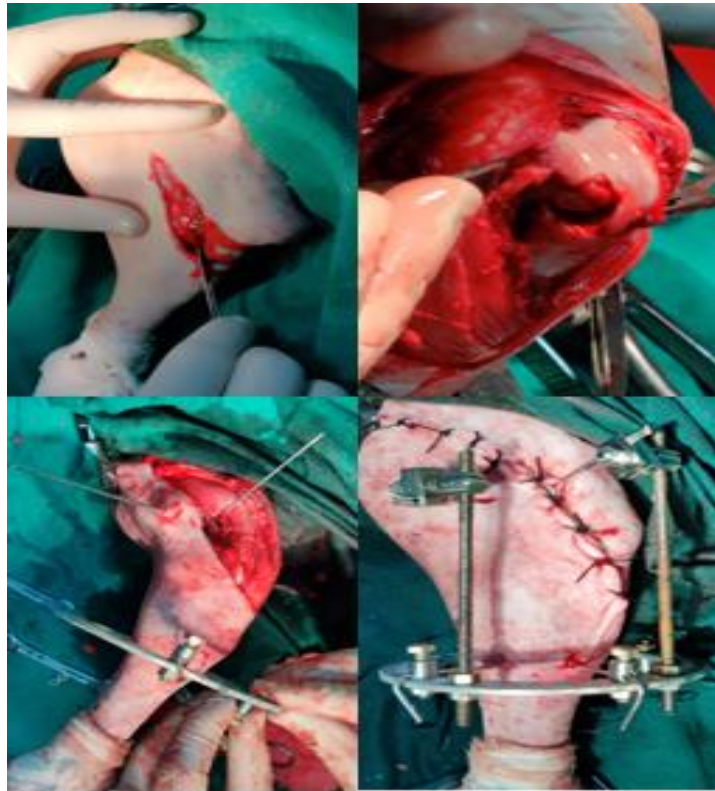


Fig. 11 Distal femur fracture fixation using hybrid external skeletal fixation

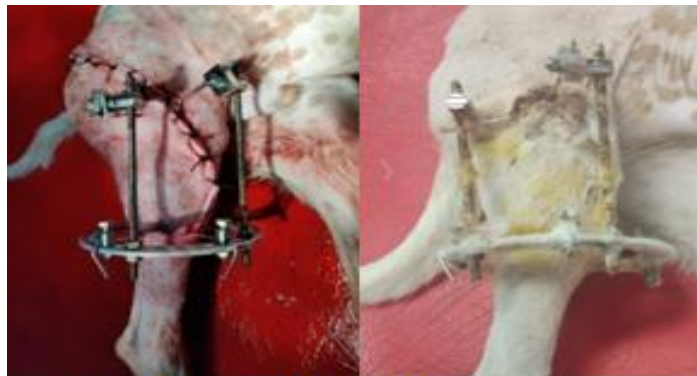

Fig. 12 (a). Incision wound healing (after 2-weeks of surgery)



Fig. 12 (b). Healing of compound humeral fracture wound (after 4th - weeks of surgery)



Fig. 13. Case presentation and follow up of different cases of present study
C6(A&B), C9(C&D), C4(E&F), C2(G&H), C1(I&J), C7(K&L), C5(N), C3(M)

4. CONCLUSIONS

Versatility of device can be improved through mechanical modifications. Muscular anatomy of upper limb bones (humerus and femur) hampers application of both circular and linear external skeletal fixation systems. Humeral and femoral fractures demands fabrication of external fixturs and hence keeping this point in mind fixturs were modified and applied. Distal radial fractures are also difficult to manage through intramedullary devices as lack of pin insertion points. Complete circular rings applied over distal fracture fragment attached with a linear assembly of proximal fragment acts as hanging fixation for distal radial fractures. Application of hybrid external fixturs can be a better choice for management of distal radial open fractures in canines. Comparatively ease of implant removal makes ESF affordable and versatile in veterinary practice especially in cases of infected fractures where other option is not available.

ACKNOWLEDGEMENTS

Authors are very thankful to Department of Veterinary Surgery and Radiology, RAJUAVS,

Bikaner for providing necessary facilities and platform to conduct study. Authors are also thankful to Dr. Praveen Bishnoi, Head of the Department for cooperation in completion of work. Special thanks to DIMSCA project funded through ICAR. Authors are highly appreciates supervision of Dr. Anil Kumar Bishnoi for conducting and completion of this study.

COMPETING INTERESTS

Authors have declared that no competing interests exist.

REFERENCES

1. Harari J. Complications of external skeletal fixation. *The Veterinary Clinics of North America: Small animal practice.* 1992;22(1):99-107.
2. Egger EL. External skeletal fixation. In: *Current techniques in small animal surgery*, Bojrab M J, IV ed. Williams and Wilkins Baltimore, USA. 1998;941-950.
3. Fossum TW. Principles of fracture diagnosis and management. In: *Small Animal Surgery E-Book*. Fifth Ed. Elsevier Health Sciences. 2019;975-1035.

4. Dwivedi DK, Ganesh TN, Ameerjan K, Ramesh G. Management of compound fracture of radius-ulna and tibia-fibula using Ilizarov's ring fixator in dogs. *Indian Journal of Veterinary Surgery*. 2009;30(2):98-100.
5. Brinker WO. *Fractures. Canine surgery*. 2nd ed. Santa Barbara: American Veterinary Publications. 1974;949-1048.
6. Beck AL, Pead MJ. The use of Ellis pins (negative profile tip-threaded pins) in external skeletal fixation in dogs and cats. *Veterinary and Comparative Orthopaedics and Traumatology*. 2003; 16(04):223-231.
7. Toombs JP. Transarticular application of external skeletal fixation. *Veterinary Clinics of North America: Small Animal Practice*. 1992;22(1):181-194.
8. De Camp External coaptation. In: *Textbook of small animal surgery*. Ed. Slatter, D.Edn.2nd. W.B. Saunders, Philadelphia. 1993;1661-1676
9. Bernarde A, Diop A, Maurel N, Viguier E. An in vitro biomechanical study of bone plate and interlocking nail in a canine diaphyseal femoral fracture model. *Veterinary surgery*. 2001;30(5):397-408.
10. Ferretti A. The application of the Ilizarov technique to veterinary medicine. In Bianchi Maiocchi A, Aronson J (eds): *Operative Principles of Ilizarov*. Baltimore, Williams & Wilkins. 1991;563.
11. Aronsohn MG, Burk RL. Unilateral uniplaner external skeletal fixation for isolated diaphyseal fractures in skeletally immature dogs. *Veterinary Surgery*. 2009;38(5):654-658.
12. Heras-Jiménez M, Rovesti GL, Nocco G, Barilli M, Bogoni P, Salas-Herreros E, Rodríguez-Quiros J. Evaluation of sixty-eight cases of fracture stabilisation by external hybrid fixation and a proposal for hybrid construct classification. *BMC veterinary research*. 2014;10(1):189.
13. Beaver LJ, Giles K, Meeson RL. Postoperative complications associated with external skeletal fixators in dogs. *Veterinary and Comparative Orthopaedics and Traumatology*. 2018;31(2):137-143.
14. Bilgili H, Kurum B, Captug O. Treatment of radius-ulna and tibia fractures with circular external skeletal fixator in 19 dogs. *Polish journal of veterinary sciences*. 2007;10(4):217.
15. Gemmill TJ, Cave TA, Clements DN, Clarke SP, Bennett D, Carmichael S. Treatment of canine and feline diaphyseal radial and tibial fractures with low-stiffness external skeletal fixation. *Journal of small animal practice*. 2004;45(2):85-91.
16. Rao JR, Kumar VG, Rao TM, Kumar DP, Reddy KCS, Raghavender KBP. Use of Hybrid External Fixation Technique in the Repair of Long Bone Fractures in Dogs. *Int. J. Curr. Microbiol. App. Sci*. 2016;5(11):579-586.
17. Ayyappan S, Shafiuzama M, Ganesh TN, Das BC, Kumar RS. A clinical study on external fixators for long bone fracture management in dogs. *Indian Journal of Veterinary Surgery*. 2009;30(2):90-92.
18. Rao JR, Kumar VG, Rao TM, Kumar DP, Reddy KCS. Management of radius-ulna and tibial diaphyseal fractures with type IIa external skeletal fixation in dogs. *The Pharma Innovation*. 2017;6(8):372.
19. Cappellari F, Piras L, Panichi E, Ferretti A, Peirone B. Treatment of antebrachial and crural septic nonunion fractures in dogs using circular external skeletal fixation: a retrospective study. *Veterinary and Comparative Orthopaedics and Traumatology*. 2014;27(04):297-305.
20. Clarke SP, Carmichael S. Treatment of distal diaphyseal fractures using hybrid external skeletal fixation in three dogs. *Journal of small animal practice*. 2006;47(2):98-103.
21. Cheong HY, Kim JH, Cha JG, Seol JW, Kim MS, Lee HB. Stabilization of Short Juxta-articular Fractures Using a Circular External Skeletal Fixator System in Dogs. 2014;31(6):523-526.
22. Calhoun JH, Li F, Ledbetter BR, Gill CA. Biomechanics of the Ilizarov fixator for fracture fixation. *Clinical orthopaedics and related research*. 1992;(280):15-22.
23. Anderson GM, Lewis DD, radarsh RM, marcellinlittle DJ, degna MT, cross AR. Circular external skeletal fixation stabilization of antebrachial and crural fractures in 25 dogs. *Journal of the American Animal Hospital Association*. 2003;39:479-498.
24. Aron DN, Toombs JP. Updated principles of external skeletal fixation. *The Compendium on continuing education for the practicing veterinarian*. 1984;6:845-858.
25. Yardimci C, ÖNYAY T, Inal KS, ÖZBAKIR BD, Ahmet ÖZAK. Management of

- Humeral Fractures in Dogs By Using Semicircular External Fixator and Intramedullary Pin Tie-in Combination. Kafkas Üniversitesi Veteriner Fakültesi Dergisi. 2018 a;24(2).
26. Cross AR, Lewis DD, Murphy ST, Rigaud S, Madison JB, Kehoe MM, Rapoff AJ. Effects of ring diameter and wire tension on the axial biomechanics of four-ring circular external skeletal fixator constructs. American journal of veterinary research. 2001;62(7):1025-1030.
 27. Yardimci C, Ozak A, Nisbet HO. Management of femoral fractures in dogs with unilateral semicircular external skeletal fixators. Veterinary Surgery. 2011;40(3):379-387
 28. Whitehair JG, Vasseur PB. Fractures of the femur. Veterinary Clinics of North America: Small Animal Practice. 1992;22(1):149-159.
 29. Farese JP, Lewis DD, Cross AR, Collins KE, Anderson GM, Halling KB. Use of IMEX SK-circular external fixator hybrid constructs for fracture stabilization in dogs and cats. Journal of the American Animal Hospital Association. 2002;38(3):279-289.
 30. Tyagi SK, Aithal HP, Prakash K, Pawde AM, Jasmeet S. Comparative biomechanical evaluation of acrylic-and epoxy-pin external skeletal fixation systems with two-and three-point fixation per segment under compressive loading. Advances in Animal and Veterinary Sciences. 2014;2(4):212-217.
 31. Yardımcı C, Özak A, Önyay T, İnal KS, Özbakır BD. Management of femoral fractures in dogs with unilateral semicircular external skeletal fixator-intramedullary pin tie-in configurations. Ankara Üniversitesi Veteriner Fakültesi Dergisi. 2018 b;65(2):129-136.
 32. Dwivedi DK, Kumar M. Treatment of Compound fracture of tibia in dog using Circular external skeletal fixator (CEF). Veterinary World. 2010;3(8):378.
 33. Marti JM, Miller A. Delimitation of safe corridors for the insertion of external fixator pins in the dog 1: Hindlimb. Journal of Small Animal Practice. 1994a;35(1):16-23.
 34. Marti JM, Miller A. Delimitation of safe corridors for the insertion of external fixator pins in the dog 2: Forelimb. Journal of Small Animal Practice. 1994b;35(2):78-85.
 35. Larin A, Eich CS, Parker RB, stubbs WP. Repair of diaphyseal femoral fracture in cats using interlocking intramedullary nails: 12 Cases (1996-2000). Journal of American Veterinary Medical Association. 2001;219(8):1098-1104.
 36. Marcellin-Little DJ. Fracture treatment with circular external fixation. Veterinary Clinics: Small Animal Practice. 1999;29(5):1153-1170.
 37. Pope ER. Fixation of tibial fractures. In: Current techniques in small animal surgery. Bojrab M J, IV ed. William and Wilkins Baltimore, USA. 1998;1050-1055.
 38. Probst. Stabilisation of fractures of the radius and ulna. In: Current techniques in small animal surgery. Bojrab M J, IV ed. William and Wilkins Baltimore, USA. 1998;1021-1031.
 39. Fragomen AT, Rozbruch SR. The mechanics of external fixation. HSS Journal. 2007;3(1):13-29.
 40. Gasser B, Boman B, Wyder D, Schneider E. Stiffness characteristics of the circular Ilizarov device as opposed to conventional external fixators; 1990.
 41. Egger EL. Complications of external skeletal fixation. A problem-oriented approach. Veterinary Clinics of North America: Small Animal Practice. 1991;21(4):705-733
 42. Palmer RH, Hulse DA, Hyman WA, Palmer DR. Principles of bone healing and biomechanics of external skeletal fixation. Veterinary clinics of North America: Small Animal Practice. 1992;22: 45-68.
 43. Chaudhari MM, Ganesh TN, David WPA. Biochemical and pathological studies during compound tibial fracture management using Ilizarov's circular external skeletal fixator in dogs. Indian Veterinary Journal. 2000;77(4):313-316.
 44. Hammer RRR, Hammerby S, Lindholm B. Accuracy of radiologic assessment of tibia shaft fracture union in humans. Clinical Orthopedics and related research. 1985;199:233-238.
 45. Fleming B, Paley D, Kristiansen T, Pope M. A biomechanical analysis of the Ilizarov external fixator. Clinical Orthopaedics and Related Research®. 1989;241:95-105.
 46. Cross AR, Lewis DD, rigaud S, RAPOFF AJ. Effect of various distal ring-block configurations on the biomechanical properties of circular external skeletal fixators for use in dogs and cats. American Journal of Veterinary Research. 2004;65:393-398.

47. Rovesti GL. Complications in external skeletal fixation. In: Complications in small animal surgery, Griffon D and Hamaide A, I ed. Wiley Blackwell, USA. 2016;704-713.
48. Radke H, Aron DN, Applewhite A, Zhang G. Biomechanical analysis of unilateral external skeletal fixators combined with IM-pin and without IM-pin using finite-element method. *Veterinary surgery*. 2006;35(1):15-23.
49. Lincoln JD. Treatment of open, delayed union, and nonunion fractures with external skeletal fixation. *Veterinary Clinics of North America: Small Animal Practice*. 1992;22(1):195-207.
50. Piermattei D, Flo G, De Camp C. Fractures: Classification, Diagnosis, and Treatment. In: Brinker, Piermattei, and Flo's Handbook of small animal orthopaedics and fracture repair, IV ed. Saunders Elsevier, Missouri, USA. 2006;25-159.
51. Johnson AL, Smith CW, Schaeffer DJ. Fragment reconstruction and bone plate fixation versus bridging plate fixation for treating highly comminuted femoral fractures in dogs: 35 cases (1987-1997). *Journal of the American Veterinary Medical Association*. 1998;213(8):1157-1161.
52. Young JW, Kovelman H, Resnik CS, Paley D. Radiologic assessment of bones after Ilizarov procedures. *Radiology*. 1990;177(1):89-93.
53. Altunatmaz K. Yucel R. Orthopaedic lesions of the antebrachium in the dog and clinical studies on these conditions. *Turkish Journal of Veterinary Surgery*. 1999;5:118-126.
54. Captug O, Bilgili H. Correction of the antebrachial deformity using circular external skeletal fixator in 7 dogs. *Pol J Vet Sci*. 2009;12(1):45-54.

© 2024 Sharma et al.; This is an Open Access article distributed under the terms of the Creative Commons Attribution License (<http://creativecommons.org/licenses/by/4.0>), which permits unrestricted use, distribution, and reproduction in any medium, provided the original work is properly cited.

Peer-review history:

The peer review history for this paper can be accessed here:
<https://www.sdiarticle5.com/review-history/112111>