

## Left hemihepatectomy and caudate resection after transarterial embolization for multiple giant liver hemangioma

Hui Jiang<sup>1</sup>, Zheyu Chen<sup>2</sup>, Jianguo Qiu<sup>3</sup>, Pankaj Prasoon<sup>4</sup>, Yong Zeng<sup>5</sup>

### SUMMARY

Hemangiomas are the most common benign tumors of the liver and need to be treated in cases where they are accompanied with symptoms, have a risk of rupture, or are hardly distinguishable from malignancy. The authors adopted Transarterial embolization preoperatively to alleviate progressive symptom and avoid rupture of tumor, using staged resection method instead of liver transplantation, and proceed for left hemihepatectomy and caudate resection with lesion of segmente! left to next surgical procedure. The resected tumor of left lobe was 20.2cm×7.3cm in size and 1680 g in weight; and the caudate hemangioma was 17.7cm×8.5cm in size and 1520 g in weight. By this approach the gainthemangioma was safely resected without any threatening complication, which should be considered a useful method of multiple giant hemangioma management.

**KEY WORDS:** Hemangioma, Transarterial embolization, Staged resection.

Pak J Med Sci January - March 2011 Vol. 27 No. 1 193-195

### How to cite this article:

Jiang H, Chen Z, Qiu J, Prasoon P, Zeng Y. Left hemihepatectomy and caudate resection after transarterial embolization for multiple giant liver hemangioma. Pak J Med Sci 2011;27(1):193-195

### INTRODUCTION

Hemangiomas are the most common benign tumors of the liver occurring in 0.4-20%.<sup>1</sup> The majority of these patients are asymptomatic and seldom present with specific clinical feature. Therefore, these lesions are usually detected incidentally through the increased use of imaging method for abdominal complaints. They occur more frequently in women than in men, and are believed to be related to levels of female hormones.<sup>2</sup> Most hemangiomas are small and need no treatment or further follow-up due to its non functional sequence and damage to adjacent organs.

Only giant liver hemangiomas with diameter lager than 5cm may give rise to mechanical complaints requires surgical intervention. In recent years, many reports regarding surgical treatment with good long-term outcome have been published.<sup>3</sup> However, there remains a very difficult challenge in surgical procedure for hemangioma larger than 20cm because of more intraoperative bleeding and the difficulty to control it, especially multiple giant liver hemangioma. Here we report the successful removal of multiple hemangiomas via left hemihepatectomy and caudate resection after transarterial embolization (TAE).

### CASE REPORT

A 49-year-old female patient visited several hospitals for the complaint of abdominal distention and progressive abdominal pain as the chief complaints. Many imaging modalities had been performed in other hospitals during the visit, and under the diagnosis of multiple giant hemangiomas, she was recommended for liver transplantation and transferred to the present hospital. Colour Doppler Ultrasonography, performed during the visit,

1. Hui Jiang,
  2. Zheyu Chen,
  3. Jianguo Qiu,
  4. Pankaj Prasoon,
  5. Yong Zeng,
- 1-5: Department of Hepatobiliary, Pancreatic Surgery, West China Hospital, Sichuan University, Chengdu 610041, Sichuan Province, China.

Correspondence:

Yong Zeng,  
E-mail: zengyong@medmail.com.cn

- \* Received for Publication: August 23, 2010  
\* Accepted: November 16, 2010

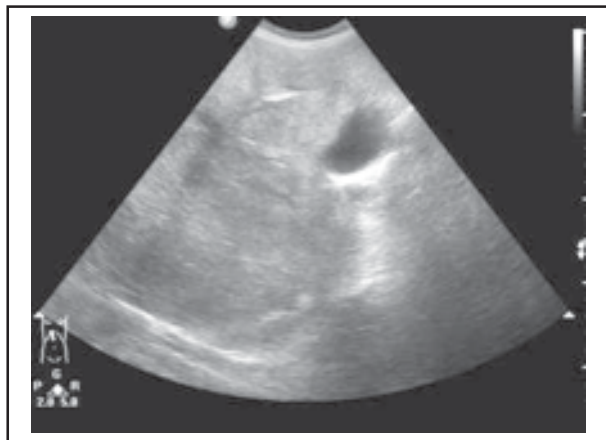


Fig-1: Abdominal colour Doppler ultrasonography detected huge hyperechoic lesions with compression to the bile ducts, portal vein and inferior vena cava (IVC), and which reveal the diagnosis of multiple giant hemangiomas.

detected three huge hyperechoic lesions with compression to the bile ducts, portal vein and inferior vena cava (IVC) (Fig-1), which revealed the diagnosis of multiple giant hemangiomas. During a physical examination upon admission, an abdominal mass was palpated from the upper abdomen to the pelvic cavity. Preoperative serum biochemical studies revealed no abnormal findings, except slight decrease of RBC to  $2.77 \times 10^{12}$  and Hb to 84g/L. Using helical CT, a non-contrast image showed a homogenous hypodense lesions contrasted with the surrounding liver parenchyma, the arterial image showed peripheral nodular enhancement, and the portal venous image showed progressive centripetal enhancement. These findings indicated multiple giant hemangiomas (Fig-2). The indocyanine green

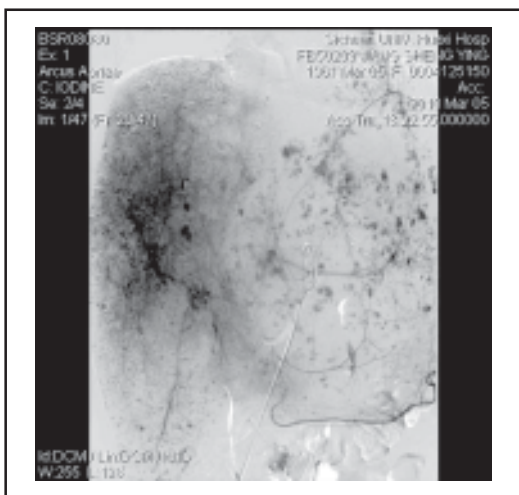


Fig-3: TAE of the left hepatic artery was conducted five days before the operation in order to prevent massive bleeding and reduction of size of hemangioma.

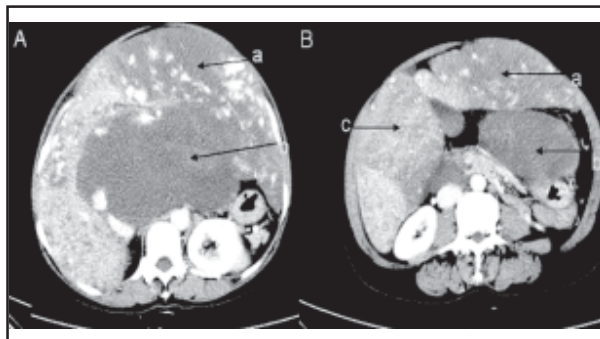


Fig-2: Abdominal CT shows homogenous hypodense lesions with the characteristic of hemangioma in right, left and caudate lobe. The arrows show three giant hemangiomas. a: a giant hemangioma of 20.2\*7.3cm in left lobe; b: another giant hemangioma of 17.7\*8.5cm in caudate lobe; c: a lesion of 7.8\*5.7cm in segment E.

clearance rate at 15 min was 1.1% (normal range <15%). TAE of the left hepatic artery was conducted five days before the operation (Fig-3), and thereafter abdominal pain alleviated, but the size decreased little.

Through a bi-coastal incision just below the diaphragm had made, the left liver was fully mobilized from their ligaments from the diaphragm and peritomeum, and left hemihepatectomy was safely conducted via Glissonian approach. And then, caudate resection was safely fulfilled (Fig-4). However, the lesion of segment E had been preserved for next resection to prevent hepatic failure. The duration of operation was 430 minutes and intraoperative blood loss was 2400 mL, and autologous transfusions of

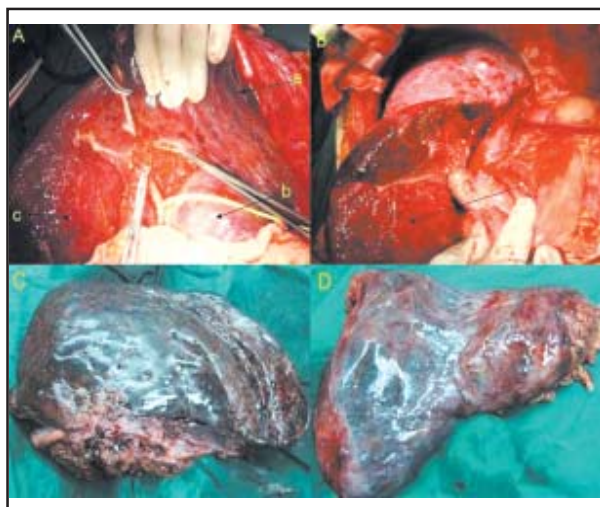


Fig-4: A: Giant liver hemangiomas on the operation table; B: the remnant of liver before the abdominal wall closure, arrow shows the lesion of segment E, which was preserved for preventing hepatic failure; C: the resected tumor of left lobe and caudate lobe (D).

1600 mL, blood transfusions of 1200 mL. The resected tumor of left lobe was 20.2cm×7.3cm in size and 1680g in weight; and the caudate hemangioma was 17.7cm×8.5cm in size and 1520g in weight. Upon histological examination, both lesions were diagnosed as cavernous-type hemangioma. The patient was stable during postoperative course. The drainage tube was removed on the fifth day and the patient was discharged on the 14th day and asked to have a second surgical procedure for removing lesion of segment-e! one year later. Follow-up has been continued for four months without any particular findings.

## DISCUSSION

Hemangiomas have specific feature when we take the assistance of imaging modalities such as USG and CT. When a hemangioma increases in size, it leads to many complications such as congestion of portal vein and bleeding to major vessels, thrombosis and infraction of major arteries leads to a frequent abdominal pain as a chief complaint when patients arrive to the hospital. In our case, the patient presented with progressive abdominal pain at the upper abdomen and abdominal distension. Various methods for the treatment of liver hemangiomas apart from resection have been described, such as ligation of hepatic artery<sup>4</sup>, liver transplantation for giant unresectable lesions<sup>5</sup> selective transcatheter arterial embolization<sup>6</sup> and radiation therapy.<sup>7</sup> However, for multiple giant hemangiomas, these methods are unsuccessful in the long term except for liver transplantation. Not all the patients with multiple giant hemangiomas are fit for liver transplantation for their good hepatic function and liver reserve ability. Considering lack of donors, high expenses for transplantation and postoperative immune rejections, we selected staged resection after TAE of left hepatic artery.

TAE is suggested as an excellent therapy for easing symptoms of giant hemangiomas, but recurrence is common because of vascular recanalization; it also can alleviate the pressure of tumor and avoid rupture preoperatively. The authors performed TAE 5 days before operation to alleviate progressive

abdominal pain. However, the mean size of tumor did not show any significant change on follow-up radiologic examinations for the might reason of arteriovenous fistula in giant hemangiomas.

Preoperative TAE can decrease the risk of bleeding during resection procedures, but for multiple giant hemangiomas (over 20cm), TAE of all the artery of lesion lobe is impossible, although theoretically available, which can cause serve damage of hepatic function and result in the loss of an opportunity for surgery. As this patient got progressive abdominal pain with three giant hemangiomas, selective TAE provided a good chance of laparotomy. However, it is difficult to deal with all the lesions at one time for the reason of preservation of enough liver parenchyma, which is critical for the success of the operation. As a result, staged resection is feasible for this patient. She underwent left hemihepatectomy and caudate lobectomy successfully, and was asked for follow up every three months consecutively, by which her hepatic function and liver imaging can be assessed for the next resection of hemangioma of segment.

## REFERENCES

1. Coumbaras M, Wendum D, Monnier-Cholley L, Dahan H, Tubiana JM, Arrive L. CT and MR imaging features of pathologically proven atypical giant hemangiomas of the liver. *Am J Roentgenol* 2002;179:1457-1463.
2. Tuncer I, Arslan H, Harman M. Two giant cavernous hemangioma caused cavernous transformation of the portal vein in a pregnant woman. *Turk J Gastroenterol* 2002;13:229-231.
3. Herman P, Costa ML, Machado MA, Pugliese V, D'Albuquerque LA, Machado MC, et al. Management of hepatic hemangioma: A 14-year experience. *J Gastrointest Surg* 2005;9:853-859.
4. Nishida O, Satoh N, Alam AS. The effect of hepatic artery ligation for irresectable cavernous hemangioma of liver. *Am Surg* 1988;54:483-486.
5. Russo MW, Johnson MW, Fair JH, Brown RS. Orthotopic liver transplantation for giant hepatic hemangioma. *Am J Gastroenterol* 1997;92:1940-1941.
6. Giavroglou C, Economou H, Ioannidis I. Arterial embolization of giant hepatic hemangiomas. *Cardiovasc Intervent Radiol* 2003;26:92-96.
7. Gaspar L, Mascarenhas F, Da Costa MS, Dias JS, Afonso JG, Silvestre ME. Radiation therapy in the unresectable cavernous hemangioma of the liver. *Radiother Oncol* 1993;29:45-50.