



# A Rare Cause of Recurrent Epistaxis: Lobular Capillary Haemangioma

L. Derkyi-Kwarteng<sup>1</sup>, P. Appiah-Thompson<sup>2\*</sup> and K. Akakpo<sup>1</sup>

<sup>1</sup>Pathology Department, School of Medical Sciences, University of Cape Coast, Ghana.

<sup>2</sup>Ear, Nose and Throat Unit, Cape Coast Teaching Hospital, Cape Coast, Ghana.

## Authors' contributions

This work was carried out in collaboration with all the authors. Authors LDK and PAT wrote the manuscript. Author KA reviewed the manuscript. All authors read and approved the final manuscript.

## Article Information

DOI: 10.9734/BJMMR/2016/20431

### Editor(s):

(1) Valeria Denninghoff, Molecular Pathology and Molecular Onco-Hematology laboratory, University Institute CEMIC, Argentina.

### Reviewers:

(1) Anonymous, Mansoura University, Egypt.

(2) Luigi Nespoli, University of Insubria, Italy.

(3) Peter Kalina, Mayo Clinic, Rochester, USA.

Complete Peer review History: <http://sciencedomain.org/review-history/11467>

Case Study

Received 28<sup>th</sup> July 2015  
Accepted 1<sup>st</sup> September 2015  
Published 19<sup>th</sup> September 2015

## ABSTRACT

Nasal lobular capillary haemangiomas are rare benign nasal tumours of vascular origin and unknown etiology. They tend to occur in both sexes depending on the age group. They usually present with unilateral nasal obstruction and recurrent epistaxis. They are usually treated by excision after having embolized the feeding vessel.

We present a case of nasal lobular haemangioma we encountered and treated by pernasal excision biopsy without prior embolization since the initial consideration was fungal sinusitis.

**Keywords:** Lobular capillary haemangioma; granuloma; pyogenic; embolization.

## 1. INTRODUCTION

Lobular capillary haemangiomas are considered as benign tumours of vascular origin and unknown etiology [1]. It is also known by some authors as pyogenic granuloma, epulis

gravidarum, eruptive haemangiomas and granulation tissue-type haemangioma. It usually occurs in the skin, mucosa of the oral cavity and tongue. Nasal cavity lobular capillary haemangioma is a very rare occurrence and if it does occur the most frequent site is the anterior

\*Corresponding author: Email: [p.appiah-thompson@uccsms.edu.gh](mailto:p.appiah-thompson@uccsms.edu.gh), [appiatee1@gmail.com](mailto:appiatee1@gmail.com);

portion of the nasal septum which is very vascularised and called area of little or locus valsalva. This area is followed by nasal vestibule and lateral wall of the nasal cavity [2-4].

The sex distribution of lobular capillary haemangioma depends on the age. In childhood and adolescent population, it is common among males; in the third and fourth decade of life it is common among females, which substantiates the role pregnancy and hormones play in its pathogenesis. Above the fifth decade the occurrence is equal in both sexes [2,4,5]

The presentation of sino-nasal haemangioma includes unilateral nasal obstruction, mucopurulent rhinorrhoea, recurrent epistaxis, headache and facial pain [1,5,6].

The risk factors associated with this disease are microtrauma, hormonal factors and prolonged intubation [1,2].

The main stay of treatment for lobular capillary haemangioma is surgical excision of mass for histologic examination [3]. Histologically it presents as proliferating capillaries with anastomosing network in a lobular pattern [2].

To enhance knowledge and increase awareness, we hope this case report will contribute to the existing paucity of literature regarding nasal hemangioma particularly in Africa.

## 2. CASE STORY

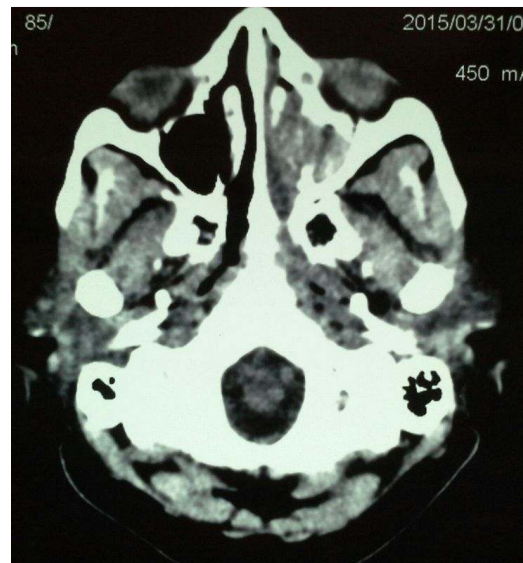A 50 year old female presented to the Ear, Nose and Throat Unit of our hospital with a 4-month history of a progressively increasing left nasal mass with associated left nasal obstruction, thick yellowish discharge and left sided headache. She had only noticed a slight left nasal bleed on one occasion. She was a known hypertensive and had no history of previous nasal surgery or packing. She was taking Tab Nifedipine 20 mg bd and Tab Methyldopa 250 mg bd.

On examination, the blood pressure was 140/70 and the other significant findings were a pale sensitive mass filling the whole of the left nasal cavity and attached to the left lateral wall. The right nasal cavity only had enlarged turbinates. The oropharynx was normal. The clinical impression was a Left Nasal Mass including a differential of malignancy.

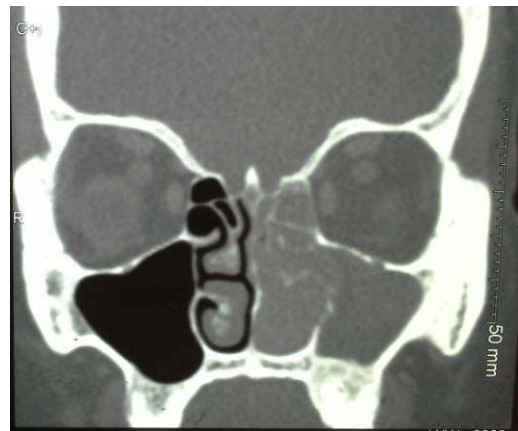
Preoperative laboratory results were as follows: Hb 12.9 g/dL, WBC  $3.99 \times 10^9/L$ , Platelet count

$228 \times 10^3/uL$ , Sickling - negative, BUE 10 mg/dl and Creatinine 61.9  $\mu\text{mol/L}$ . Electrocardiogram was normal. Chest x-ray was also normal.

Pre and post contrast CT scans were taken and these showed a left nasal mass with heterogeneous enhancement and mixed density with remodeling or erosion of the lateral wall as shown in Figs. 1 and 2. There was associated stasis of fluid in the maxillary, sphenoid and ethmoidal sinuses.



**Fig. 1. Axial CT scan of the nasal cavities showing the tumour in the left nasal cavity**



**Fig. 2. Coronal CT Scan showing the left heterogeneously - enhancing nasal tumour**

Pernasal excision of the mass was done. There was moderate intraoperative bleeding thus BIPP (Bismuth Iodoform Paraffin Paste) gauze was used to pack the nose. The pack was removed

after 48 hours. Two months after the procedure patient is asymptomatic and breathes comfortably through the nose.

Histology revealed an ulcerated polyp with lobular architecture. The lobules were composed of network of proliferating capillaries and mixed inflammatory infiltrates mainly of lymphocytes, plasma cells and neutrophils (Fig. 3).

### 3. DISCUSSION

Lobular capillary haemangioma is a benign, painless, rapidly growing papule or polyp mostly found on the skin and mucosal surfaces. More commonly it is found in the head and neck region. The nasal type is rare as found in this patient. These haemangiomas tend to regress with time except those which are frequently traumatized like on the buttocks and those related to vital structures like the nose, eyes and mouth [7,8].

These tumours were initially called '*Pyogenic granuloma*.' They had in 1897 been described as small vascular tumours of fungal origin by Poncet and Dor [3]. Our suspicion of a fungal sinusitis in our patient's case might have been justified. Later the term '*Pyogenic granuloma*' was found to be a misnomer in that these haemangiomas were neither infectious nor granulomatous. The name was 'corrected' in 1980 by Mills et al. They termed it '*Lobular capillary haemangioma*.' [1]. It was found that the lesion was comprised of lobular capillary proliferation with extensive

edema and acute and chronic inflammatory infiltrate [9,10].

Differential diagnoses for the lobular capillary haemangiomas are *juvenile angiofibroma* which has a uniform fibrous stroma and *angiomatous polyp* which lacks organization [10]. It is advisable today to consider lobular capillary hemangioma as a strong differential when dealing with a suspected case of nasal angiofibroma due to the radiologic and microscopic similarity [8]. Other differentials that must be considered are papilloma, malignant melanoma, Kaposi sarcoma and antrochoanal polyp [11].

In the West African region, getting an idea of the true incidence of lobular capillary haemangiomas is difficult since the keeping of hospital records is mostly inadequate [1]. The high cost of treatment for our patients who are mostly poor and thus present late to the hospital is another limiting factor [12]. Histology in our country is not covered by the National Health Insurance thus many clients cannot afford this for most nasal biopsies to be examined' [13].

In patients under 18 it is more common in males whilst in those between 18 and 39 years, females dominate. A third of these lesions occur after microtrauma. It has also been found to occur on the gingiva of 1% of pregnant women. It is termed '*granuloma gravidarum*' in this instance [7].

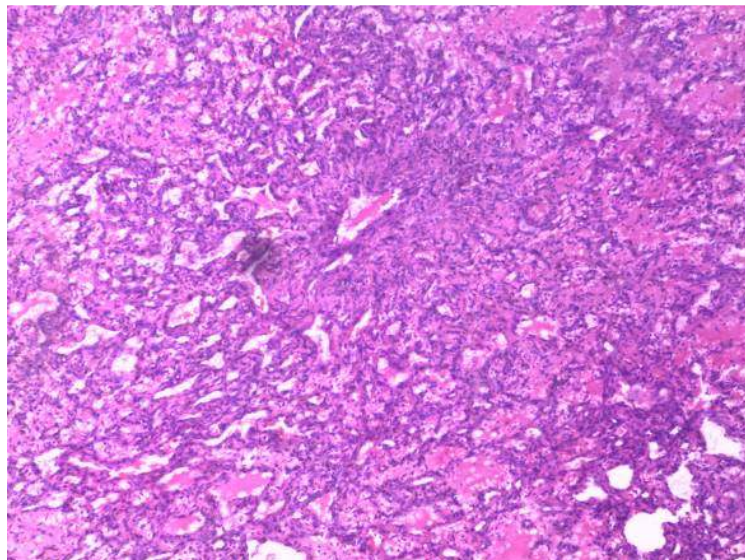


Fig. 3. Microscopic Image of the Nasal lobular capillary haemangioma

This type is said to regress after delivery thus believed to be hormone - related. It may instead become fibrotic and not regress [9]. Our case is a post menopausal woman thus not in the category of pregnancy - related pyogenic granuloma.

The lesion in the nose mostly presents as a nasal mass attached to the nasal septum which ulcerates and easily bleeds [7]. It may also arise from the roof or the lateral wall. The lesion in this case was attached to the lateral wall. If the tumour fills the entire nasal cavity it is described as a 'giant capillary haemangioma' [14].

Imaging of the nose and paranasal sinuses is key in the diagnosis of lobular capillary haemangiomas. Computed tomography (CT) scans and magnetic resonance imaging are commonly used. CT scans tend to be superior as they demonstrate the strongly enhancing nature of the tumour and the bony destruction in the nasal walls [15]. There was erosion of the left lateral nasal wall on the scans of our patient.

The nasal lobular capillary hemangioma is best treated by complete excision by endoscopic surgery [6]. Embolization of the feeding vessels may also be performed to decrease the preoperative vascularity. Transnasal excision was done in this instance without embolization since the differential diagnosis considered prior to surgery did not include lobular capillary hemangioma. Endoscopic facilities however are also not available at our centre.

Recurrence is rare though it is known that incomplete excision can lead to recurrence [7].

#### 4. CONCLUSION

Lobular capillary haemangioma should be strongly considered when dealing with a unilateral, rapidly enlarging nasal mass with episodes of epistaxis. Complete excision of the tumour must be aimed at.

#### CONSENT

Consent for this publication was obtained from the patient.

#### ETHICAL APPROVAL

This is not applicable.

#### COMPETING INTERESTS

Authors have declared that no competing interests exist.

#### REFERENCES

1. Ayontunde JF, Oluwatosin SA, Clement AO and Aderemi AA: Nasal septal lobular capillary haemangioma in West Africa sub region: A case report. *Case Journal*. 2009; 2:8952
2. Kumar R, Babu M, Venkatarajamma P, Mishap U. Pyogenic granuloma of the nasal septum: A case report and literature review. *IJOHNS*. 2014;3:190-194.
3. Poncet A, Dor L. Botryomycose humaine. *Rev Chir (Paris)*. 1897;18:996.
4. Hartzell MB. Granulation pyogenicum (botryomycosis of French authors). *J Cutaneous Dis*. 22:520-523.
5. Mills SE, Cooper PH, Fechner RE. Lobular capillary haemangioma; the underlying lesion of pyogenic granuloma. A study of 73 cases from the oral and nasal mucous membranes. *Am J Surg Pathol*. 1980; 4:470-479.
6. Lee HM, Lee SH, Hwang SJ. A giant pyogenic granuloma in the nasal cavity caused by nasal packing. *Eur Arch Otorhinolaryngol*. 2002;259:231-233.
7. Johnson JT, Bailey BJ. *Head and neck surgery - otolaryngology*. 4<sup>th</sup> edition. Lippincott Williams & Wilkins. 2006;180-1:2736:2746
8. Prashant P, Singla S, Mane R, Jagdeesh KS. Nasal lobular capillary hemangioma. *J Clin Imaging Sci*. 2013;3:40.
9. Kumar V, Abbas AK, Fausto N, Mitchell RN. *Robbins basic pathology*. 8<sup>th</sup> edition. Saunders/Elsevier. 2007;373.
10. Cheng L, Bostwick DGT. *Essentials of anatomic pathology*. 2<sup>nd</sup> Edition. Humana Press. 2006;18:24.
11. Simo R, de Carpentier J, Rejali D, Gunawardena WJ. Paediatric pyogenic granuloma presenting as a unilateral nasal polyp. *Rhinolog*. 1998;36:136-138.
12. Baidoo KK, Kitcher ED. Recurrent respiratory papillomatosis: The korle bu experience. *Ghana Medical Journal*. 2012; 46:ISSN 0016-9560.
13. Recommendations from a meeting on health of the elderly and policy implications in Ghana organized by the Ghana public health association. Available: [ghanaweb.com/GhanaHomePage/health](http://ghanaweb.com/GhanaHomePage/health)
14. Gatti P, Capelli M. A Case of capillary hemangioma of the nasal septum in a patient with chronic ischemic heart disease

- and antiplatelet treatment non-suspendable. Journal of Medical Cases. 2015;6:59- 61.
15. Lee DG, Lee SK, Chang HW, Kim JY, Lee HJ, Lee SM, Kwon JH, Woo S. CT features of lobular capillary hemangioma of the nasal cavity. Am J Neuroradiol. 2010; 31(4):749–54.

---

© 2016 Derkyi-Kwarteng et al.; This is an Open Access article distributed under the terms of the Creative Commons Attribution License (<http://creativecommons.org/licenses/by/4.0>), which permits unrestricted use, distribution, and reproduction in any medium, provided the original work is properly cited.

*Peer-review history:*  
*The peer review history for this paper can be accessed here:*  
<http://sciencedomain.org/review-history/11467>