

## Single scrotal-incision orchidopexy for palpable undescended testis in children

Mohamed Zouari, Mahdi Ben Dhaou, Mohamed Jallouli & Riadh Mhiri

To cite this article: Mohamed Zouari, Mahdi Ben Dhaou, Mohamed Jallouli & Riadh Mhiri (2015) Single scrotal-incision orchidopexy for palpable undescended testis in children, Arab Journal of Urology, 13:2, 112-115, DOI: [10.1016/j.aju.2014.11.003](https://doi.org/10.1016/j.aju.2014.11.003)

To link to this article: <https://doi.org/10.1016/j.aju.2014.11.003>



© 2014 Arab Association of Urology



Published online: 05 Apr 2019.



Submit your article to this journal [↗](#)




Article views: 460



View related articles [↗](#)



View Crossmark data [↗](#)



PEDIATRIC UROLOGY  
ORIGINAL ARTICLE

# Single scrotal-incision orchidopexy for palpable undescended testis in children



Mohamed Zouari \*, Mahdi Ben Dhaou, Mohamed Jallouli, Riadh Mhiri

Department of Paediatric Surgery, Hedi Chaker Hospital, Sfax, Tunisia

Received 30 July 2014, Received in revised form 2 November 2014, Accepted 7 November 2014  
Available online 8 December 2014

## KEYWORDS

Palpable undescended testis;  
Single scrotal-incision;  
Orchidopexy;  
Scrotum

## ABBREVIATIONS

SSIO, single scrotal-incision orchidopexy

**Abstract Objective:** To evaluate the single scrotal-incision orchidopexy (SSIO) technique in patients with an undescended testis palpable in the inguinal canal or below the external inguinal ring.

**Patients and methods:** Between January 2011 and December 2013 we performed 100 SSIOs in 89 patients. The mean (range) follow-up was 9 (3–36) months.

**Results:** In 88 testes the SSIO was performed with no difficulties. In four patients an additional dissection by opening the external ring and canal was necessary; none of these patients developed an inguinal hernia after surgery. In eight patients conversion to an inguinal approach was necessary because of difficulty in controlling the hernial sacs and inadequate mobilisation. At the follow-up assessment, of the 89 patients, none developed testicular atrophy, one (1%) had wound dehiscence and four (5%) had a scrotal haematoma. There was no statistically significant difference between the testicular size at baseline and that during the follow-up. At 3 months after surgery the overall cosmetic result was excellent.

**Conclusion:** The SSIO is minimal-access surgery allowing less dissection, less discomfort for the patient, rapid healing, excellent cosmetic results and a good success rate. This technique is safe and effective for undescended testes palpable in the inguinal canal or below the external inguinal ring.

© 2014 Arab Association of Urology. Production and hosting by Elsevier B.V. This is an open access article under the CC BY-NC-ND license (<http://creativecommons.org/licenses/by-nc-nd/3.0/>).

\* Corresponding author at: Ain Road 3042, Sfax, Tunisia.  
Tel.: +216 97459586.

E-mail address: [zouarimohamed.1982@yahoo.fr](mailto:zouarimohamed.1982@yahoo.fr) (M. Zouari).  
Peer review under responsibility of Arab Association of Urology.



Production and hosting by Elsevier

## Introduction

The incidence of undescended testis in different studies varies from 30% in premature children to 1–3% in children born at term [1–3]. Most undescended testes are

palpable [2]. The traditional inguinal orchidopexy, requiring two incisions, is a well-established technique that has commonly been regarded as the standard for managing undescended testes. This technique allows adequate mobilisation of the testis and spermatic vessels, and ligation of the associated hernia. Although the role of the transscrotal approach to the undescended testis remains controversial, this technique is gaining popularity [4]. We evaluated a single scrotal-incision orchidopexy (SSIO) in patients with an undescended testis palpable in the inguinal canal or below the external inguinal ring.

### Patients and methods

Between January 2011 and December 2013, we performed 100 SSIOs in 89 patients. We excluded children with an ectopic testis (three) and those who had a history of previous inguinal surgery. All children were examined while supine, on at least two occasions, before and after the induction of general anaesthesia (Fig. 1), by the primary surgeon to confirm the diagnosis of a palpable undescended testis and to determine its location. Testicular size was measured at baseline and during the follow-up. All procedures were performed by one surgeon.

The principle surgical steps included: A high transverse scrotal incision; creation of a dartos pouch; deepening the incision through the layers of the scrotum down to the testis; releasing the gubernacular attachments to enable identification of the testis within the cremasteric fibres, a patent processus vaginalis, and the cord structures; separating the cremasteric fibres and hernia sac from the cord structures; mobilising the

cranial sac under traction; high ligation of the hernia sac at the level of its origin at the internal inguinal ring (Fig. 2); placing the testis into the dartos pouch, and fixing it to the scrotal septum; and closing the scrotal skin with dissolvable sutures.

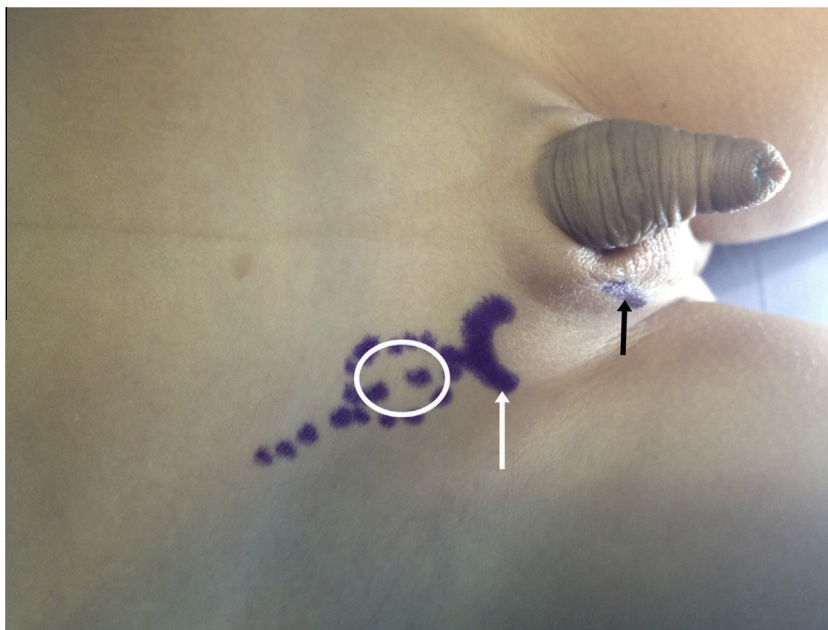
Optional surgical steps are used when additional cord length is required and include additional dissection through the same incision by opening the external ring and canal, and retroperitoneal dissection via a standard inguinal incision when additional length was still needed.

The operative duration was recorded. The follow-up assessments were at 2 weeks, 3 and 6 months and 1 year after surgery, to determine the position and size of the testis, and to identify any other complications.

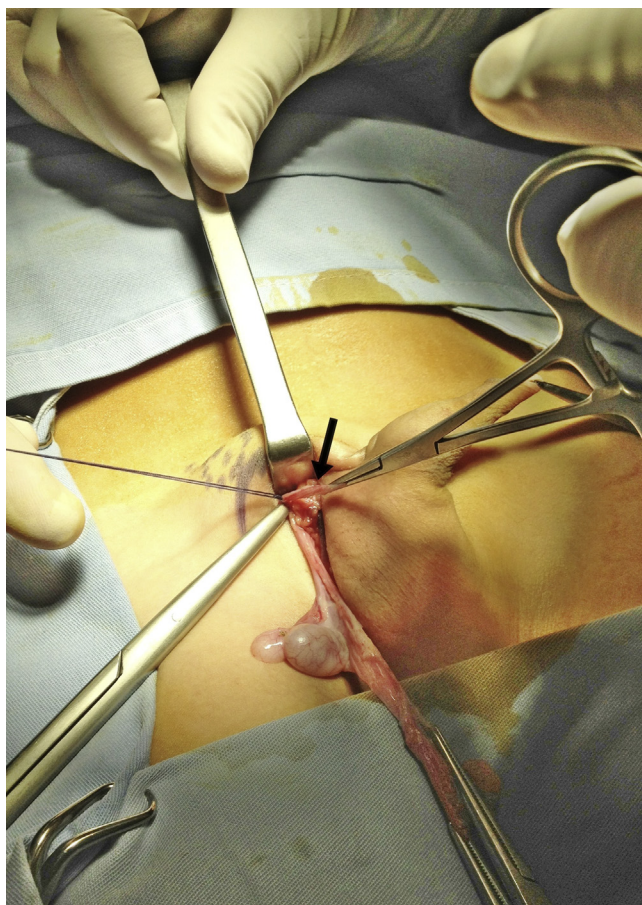
### Results

The undescended testes were right-sided in 44 patients, left-sided in 34 and bilateral in 11. The mean (range) age of the patients was 3.8 (0.75–12) years at the time of surgery. SSIO was performed before 18 months of age in 18 patients (22 testes) and after 5 years of age in 33 (36 testes). In these 33 patients a palpable undescended testis was detected at 5–6 years old (at the pre-school medical examination).

In 88 testes the SSIO was performed with no difficulties. In four cases an additional dissection was needed, by opening the external ring and canal; none of these patients developed an inguinal hernia after surgery. In eight patients conversion to an inguinal approach was necessary because of difficulty in controlling the hernial sacs, and inadequate mobilisation.



**Figure 1** A preoperative image showing the presumed location of the scrotal incision (black arrow), external inguinal ring (white arrow) and testis position (circle).



**Figure 2** The intraoperative appearance of scrotal orchidopexy in a patient with an inguinal hernia (arrow).

The patients were divided into two groups, such that in group 1 (76 testes) the testis was located below the external ring, and in group 2 (24 testes) it was located in the inguinal canal. The SSIO was successful in 97% of group 1 and 75% of group 2. The mean (SD) operative duration was 17 (3.2) min and 27.5 (3.5) min, respectively. There was a hernia sac in 24% and 71%, respectively.

The mean (range) follow-up was 9 (3–36) months, and of the 89 patients, none developed testicular atrophy, one (1%) had wound dehiscence, and four (5%) had a scrotal haematoma. There was no statistically significant difference between the testicular size at baseline and that during the follow-up. At 3 months after surgery the overall cosmetic result was excellent. One patient with a hernia sac had a hernia recurrence. None of the eight patients undergoing conversion to an inguinal approach developed a hernia recurrence after surgery.

## Discussion

The traditional technique for treating a palpable undescended testis requires inguinal and scrotal incisions. The inguinal incision is essential for adequate mobilisa-

tion of the undescended testis and ligation of the hernia sac. Through this incision the inguinal canal can be opened easily, the cord structures identified and the hernia sac dissected and managed by high ligation. This allows an adequate length of the spermatic cord. The scrotal incision is made to place the testis into the dartos pouch, and fix it to the scrotal septum [5,6]. However, most undescended testicles are palpable at the external inguinal ring or distally. The distance between the external ring and the upper scrotum is short. Therefore orchidopexy can be done through a single scrotal incision. This technique is less invasive than the standard inguinal technique. It should be used for undescended testes located distal to the external inguinal ring [1].

Bianchi and Squire [7] and Hazebroek et al. [8] showed that, in most cases of palpable undescended testes, the dissection of the cremaster and the processus vaginalis allows an adequate length of spermatic cord elements. Therefore the testes can be placed into the dartos pouch with no tension. Callewaert et al. [9] suggested that SSIO has many advantages over the traditional inguinal approach, as the operation is quicker and the cosmetic result is better. The single scrotal approach has been shown to be effective in managing primary and secondary cryptorchidism and communicating hydroceles, but the success of this technique for inguinal hernias has not been confirmed [10]. Redman [11] explained that this technique has not gained widespread acceptance because the ligation of the processus through a high scrotal incision is complex. However, the importance of ligating the processus vaginalis in managing undescended testes is controversial. Parsons et al. [12], in their series of pre-scrotal orchidopexies, reported that an inguinal incision was necessary to ligate the patent processus vaginalis, which was found in 20% of cases. Others [5,13,14] suggested that the long-term outcome of orchidopexy is unaffected by not ligating the hernia sac. Several recent studies on scrotal orchidopexy found that a patent processus vaginalis could be dissected from the cord structures through the inguinal canal, with the aid of traction of the sac [3,9,15–18].

In the present study SSIO was used in patients with an undescended testis palpable in the inguinal canal or below the external inguinal ring, and the success of the technique was evaluated. An inguinal hernia was found in 35% of patients and was repaired with no problems. We believe that ligation of a patent processus vaginalis is feasible in the trans-scrotal approach. The hernia sac can be mobilised under traction through the external ring and ligated at the level of its origin at the internal inguinal ring. In some cases additional dissection is needed to allow the testicle to lie comfortably in the scrotum, and this can be done through the same incision by opening the external ring and canal.

SSIO has many advantages; it is simple and easy to learn and master. It offers minimal dissection and

minimal trauma to the inguinal region. As a result, this technique causes less postoperative pain or swelling. Using a single scrotal incision also has the advantages of less pain, as there is no inguinal incision, and gives better cosmetic results and a quicker operation [14,19,20].

In conclusion, the SSIO is minimal-access surgery that requires less dissection, causes less discomfort for the patient, and provides rapid healing, excellent cosmetic results and a good success rate. This technique is safe and effective for undescended testicles palpable in the inguinal canal or below the external inguinal ring.

#### Source of funding

None.

#### Conflict of interest

None.

#### References

- [1] Caruso AP, Walsh RA, Wolach JW, Koyle MA. Single scrotal incision orchiopexy for the palpable undescended testicle. *J Urol* 2000;**164**:156–8.
- [2] Kanemoto K, Hayashi Y, Kojima Y, Tozawa K, Mogami T, Kohri K. The management of impalpable testis with combined groin exploration and subsequent transinguinal laparoscopy. *J Urol* 2002;**167**:674–6.
- [3] Bassel YS, Scherz HC, Kirsch AJ. Scrotal incision orchiopexy for undescended testes with or without a patent processus vaginalis. *J Urol* 2007;**177**:1516–8.
- [4] Gordon M, Cervellione RM, Morabito A, Bianchi A. 20 years of transscrotal orchidopexy for undescended testis: results and outcomes. *J Pediatr Urol* 2010;**6**:506–12.
- [5] Handa R, Kale R, Harjai M, Minocha A. Single scrotal incision orchiopexy for palpable undescended testis. *Asian J Surg* 2006;**29**:25–7.
- [6] Misra D, Dias R, Kapila L. Scrotal fixation. A different surgical approach in the management of the low undescended testes. *Urology* 1997;**49**:762–5.
- [7] Bianchi A, Squire BR. Transscrotal orchidopexy: orchidopexy revised. *Pediatr Surg Int* 1989;**4**:189–92.
- [8] Hazebroek FW, de Muinck Keizer-Schrama SM, van Maarschalkwerd M, Visser HK, Molenaar JC. Why luteinizing hormone-releasing nasal spray will not replace orchidopexy in the treatment of boys with undescended testes. *J Pediatr Surg* 1987;**22**:1177–82.
- [9] Callewaert PR, Rahnama MS, Biallosterski BT, Van Kerrebroeck PE. Scrotal approach to both palpable and impalpable undescended testes: should it become our first choice? *Urology* 2010;**76**:73–6.
- [10] Kirn KK. High scrotal incision for scrotal pouch orchiopexy. *Urology* 1996;**48**:131–2.
- [11] Redman JF. Simplified technique for scrotal pouch orchiopexy. *Urol Clin North Am* 1990;**17**:9–12.
- [12] Parsons JK, Ferrer F, Docimo SG. The low scrotal approach to the ectopic or ascended testicle. prevalence of patent processus vaginalis. *J Urol* 2003;**169**:1832–3.
- [13] Mohta A, Jain N, Irniraya KP, Saluja SS, Sharma S, Gupta A. Non-ligation of the hernial sac during herniotomy: a prospective study. *Pediatr Surg Int* 2003;**19**:451–2.
- [14] Gharaibeh KI, Matani YY. To ligate or not to ligate the hernial sac in adults? *Saudi Med J* 2000;**21**:1068–70.
- [15] Dayanc M, Kibar Y, Irkilata HC, Demir E, Tahmaz L, Peker AF. Long-term outcome of scrotal incision orchiopexy for undescended testis. *Urology* 2007;**70**:786–8.
- [16] Irkilata HC, Dayanc M, Kibar Y, Musabak U, Yesilkaya E, Oral E, et al. Effect of scrotal incision orchiopexy on serum inhibin B levels and comparison with classic inguinal orchiopexy. *Urology* 2008;**72**:525–9.
- [17] Al-Mandil M, Khoury AE, El-Hout Y, Kogon M, Dave S, Farhat WA. Potential complications with the prescrotal approach for the palpable undescended testis? A comparison of single prescrotal incision to the traditional inguinal approach. *J Urol* 2008;**180**:686–9.
- [18] Yucel S, Celik O, Kol A, Baykara M, Guntekin E. Initial prescrotal approach for palpable cryptorchid testis: results during a 3-year period. *J Urol* 2011;**185**:669–72.
- [19] Ramzan M, Sheikh AH, Qureshi MS, Zubair M, Majid F. Single incision transscrotal versus standard inguino-scrotal orchidopexy in children with palpable undescended testis: our experience from April 2007 to April 2010. *Pak J Med Sci* 2012;**28**:827–9.
- [20] Warde N. Orchidopexy via a single scrotal incision in boys with palpable and impalpable undescended testis. *Nat Rev Urol* 2010;**7**:180.