

Urothelial bladder tumour in childhood: A report of two cases and a review

Usama N. Rifat, Nader Y. Hamadalla, Khalid C. Chiad Safi, Salwan S. Al Habash & Mustafa Mohammed

To cite this article: Usama N. Rifat, Nader Y. Hamadalla, Khalid C. Chiad Safi, Salwan S. Al Habash & Mustafa Mohammed (2015) Urothelial bladder tumour in childhood: A report of two cases and a review, Arab Journal of Urology, 13:2, 116-121, DOI: [10.1016/j.aju.2014.11.002](https://doi.org/10.1016/j.aju.2014.11.002)

To link to this article: <https://doi.org/10.1016/j.aju.2014.11.002>



© 2014 Arab Association of Urology



Published online: 05 Apr 2019.



Submit your article to this journal [↗](#)




Article views: 291



View related articles [↗](#)



View Crossmark data [↗](#)



PEDIATRIC UROLOGY
REVIEW

Urothelial bladder tumour in childhood: A report of two cases and a review



Usama N. Rifat ^{a,*}, Nader Y. Hamadalla ^a, Khalid C. Chiad Safi ^a,
Salwan S. Al Habash ^a, Mustafa Mohammed ^b

^a Jordan Hospital, Amman, Jordan,

^b Sunderland Hospital, Sunderland, UK

Received 20 July 2014, Received in revised form 8 November 2014, Accepted 8 November 2014
Available online 26 November 2014

KEYWORDS

Urothelial;
Bladder;
Tumour;
Childhood

ABBREVIATIONS

US, ultrasonography;
PUNLMP, papillary urothelial neoplasm of low malignant potential;
UC, urothelial carcinoma;
TURBT, transurethral resection of the bladder tumour;
SEER, surveillance, epidemiology and results

Abstract Urothelial bladder tumour in childhood is extremely rare, and almost all the reported cases have been low-grade tumours with a favourable outcome. Here we review 57 reports comprising 127 cases, and we report two new cases.

© 2014 Arab Association of Urology. Production and hosting by Elsevier B.V. This is an open access article under the CC BY-NC-ND license (<http://creativecommons.org/licenses/by-nc-nd/3.0/>).

* Corresponding author at: Israa Hospital, Amman, Jordan.

E-mail address: usama.rifat@yahoo.com (U.N. Rifat).

Peer review under responsibility of Arab Association of Urology.

Introduction

Urothelial bladder tumour in childhood is extremely rare [1]. Deming (cited in [2]) reported the first such case, in a patient aged < 10 years, in 1924. In 1969, Javadpour



Production and hosting by Elsevier

Table 1 A review of the 127 cases: All the studies were of level of evidence 5.

Ref.	Cases/sex	Age (years)	Cell type	Treatment	Outcome
[1]	1/M	4	High-grade (grade 3), muscle-invasive Papillary UC, stage T2b	TURBT, R after 3 months, Partial cystectomy + chemo	NR at 6 months
[2]	6/4M/2F	6–17	Grade I TCC	TURBT	NR
[3]	8/6M/2F	<18	Two G1Ta, 1 G1T1, 1 G2T1, and 5 G2Ta	TURBT	NR 8–27 years
[4]	1/M	10	Grade I well-differentiated	TURBT	Pending
[5]	12/M	<21	Low-grade/low-stage	TURBT	1 patient had 1 R
[6]	1/F	9	Grade 1 TCC	TURBT	N/A
[7]	5/M	11–18	Low-grade	TURBT	N/A
[8]	7/M + F	<16	Low-grade	TURBT	NR after 18 months
[9]	1/M	5	High-grade	Partial cystectomy	NR after 1 year
[10]	1/F	16	High-grade invasive TCC	Radio- and chemotherapy	Died from metastatic disease
[12]	1/F	9	Low-grade	TURBT	NR in 4 years
[13]	2/M/F	15/18	Superficial TCC	TURBT	N/A
[14]	2/F	8/9	Grade 1 stage pTa	TURBT	NR in 4 years
[15]	1/F	12	Superficial TCC	TURBT	N/A
[16]	1/M	10	Grade 2 TCC with lamina propria invasion	TURBT + Mitomycin	N/A
[17]	1/F	10	PUNLMP	TURBT	NR in 9 months
[18]	23/19M/4F	4–20	2 papilloma, 10 PUNLMP, 8 low grade, 3 high grade	TURBT	3 R in 13 years
[19]	1/M	12	Ta grade II	TURBT	NR in 2 months
[20]	1/M	13	Low grade	TURBT	N/A
[21]	1/F	10	Grade I papillary TCC	TURBT	R in 2 years
[22]	1/M	18	Grade 1 TCC	TURBT	NR in 2 years
[24]	2/M	<20	Grade 1 and 2	TURBT	N/A
[25]	1/M	8	Grade I superficial (pTa)	TURBT	NR in 5 years
[26]	2/M	<10	Low-grade	TURBT	N/A
[27]	6/4M/2F	10–22	Low-grade and low-stage	TURBT	N/A
[28]	1/M	8	Papillary TCC with lymphangiectasia	TURBT	N/A
[29]	1/M	11	Low-grade	TURBT	N/A
[30]	1/M	13	Low-grade	TURBT	N/A
[32]	1/F	8	Grade 1 TCC	TURBT	N/A
[33]	7/M	<20	Low-grade	TURBT	NR
[34]	1/M	14	Papillary noninvasive TCC	TURBT	N/A
[35]	3/M	<18	Low-grade	TURBT	Two R
[37]	1/M	<18	Grade II to III + submucosal invasion	TURBT	NR in 30 months
[38]	1/F	10	Papillary carcinoma	TURBT	N/A
[40]	1/M	16	Grade I–II	TURBT	NR in 2 years
[41]	2/M	2–3	Papillary epithelial tumours	TURBT	N/A
[45]	1/M	11	Papillary TCC	TURBT	N/A
[46]	8/5M/3F	10–20	Low-grade	TURBT	NR in 7 years
[47]	1/M	<18	Low-grade	TURBT	N/A
[50]	1/M	10	Grade 1, noninvasive TCC	TURBT	NR in 2 years
[52]	2/M	<18	Low-grade	TURBT	1 R
[53]	4/2F/2M	2–18	Low-grade TCC	TURBT	NR at 3/6/4/1.5 years
[54]	1/F	16	Papillary TCC, grade I/Costello syndrome	TURBT	NR in 2 years
Present	2/M	5–12	Low-grade, 1 PUNLMP	TURBT	NR in 3 years

NR, no recurrence; R, recurrence; N/A, not available.

PUNLMP cases before 2004 were excluded.

No abstract available in [39] (two cases), [43] (one case) and [44] (one case).

Some references were reviews or analysis without reporting the number of cases.

and Mostofi [2] identified 40 primary epithelial bladder tumours in the first two decades of life from 10,000 total cases.

A more recent review of previous reports identified 125 patients who were aged <20 years, of whom only 20 were aged <10 years [3], and the origin of such cases was mesodermal; reports on this topic are very limited. These tumours have been shown to have a low grade of malignancy, showing little tendency to recur [4],

and have a good prognosis. Here we review previous cases and report two new cases of urothelial bladder tumour.

Methods

We reviewed the databases of PubMed and Hinari for reports in English, searched using the keywords ‘bladder’, ‘transitional cell carcinoma’ and ‘children’. We

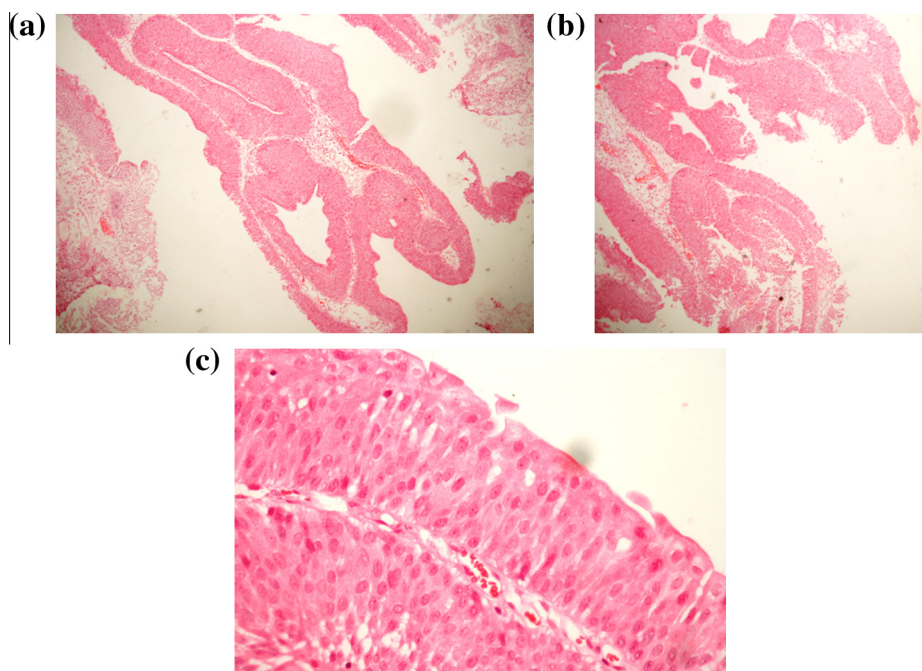


Figure 1 (a–c) Histological findings at both low ($\times 100$) and high ($\times 400$) power. Haematoxylin and eosin stain.

identified 57 articles [1–57], comprising 127 cases (Table 1). We also describe two new cases.

Case 1

A 5-year-old boy from Hadramout, Yemen, presented in 2009 with 1 week of gross haematuria and interrupted urinary stream. There was no significant family, present or previous history. On physical examination at the time of presentation, the patient's vital signs were stable. The abdomen was not tender and not distended. There were no associated anomalies.

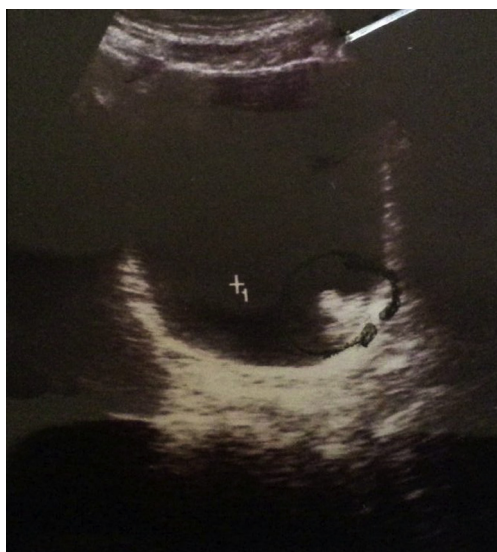

Figure 2 An ultrasonogram showing the soft-tissue lesion in the left bladder wall.

There was no recurrence after a 3-year follow-up using abdominal ultrasonography (US) and cystoscopy, with assessments every 3 months in the first year then every 6 months thereafter. Fig. 1(a–c) shows the histological findings. Sections showed elongated papillary fronds lined by several layers of transitional cells with slightly enlarged crowded nuclei. There was no frank pleomorphism and no stromal invasion. The diagnosis was papillary urothelial neoplasm of low malignant potential (PUNLMP, WHO grade I).

Case 2

A 12-year-old boy from Baghdad, Iraq, presented in August 2013 with two recent attacks of painless haematuria and clots. His medical history indicated a previous

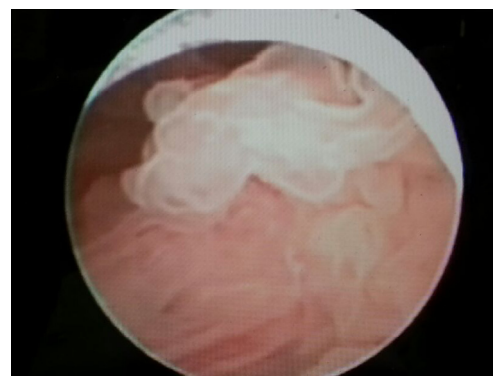


Figure 3 A cystoscopic view of a villous lesion above the left ureteric orifice.

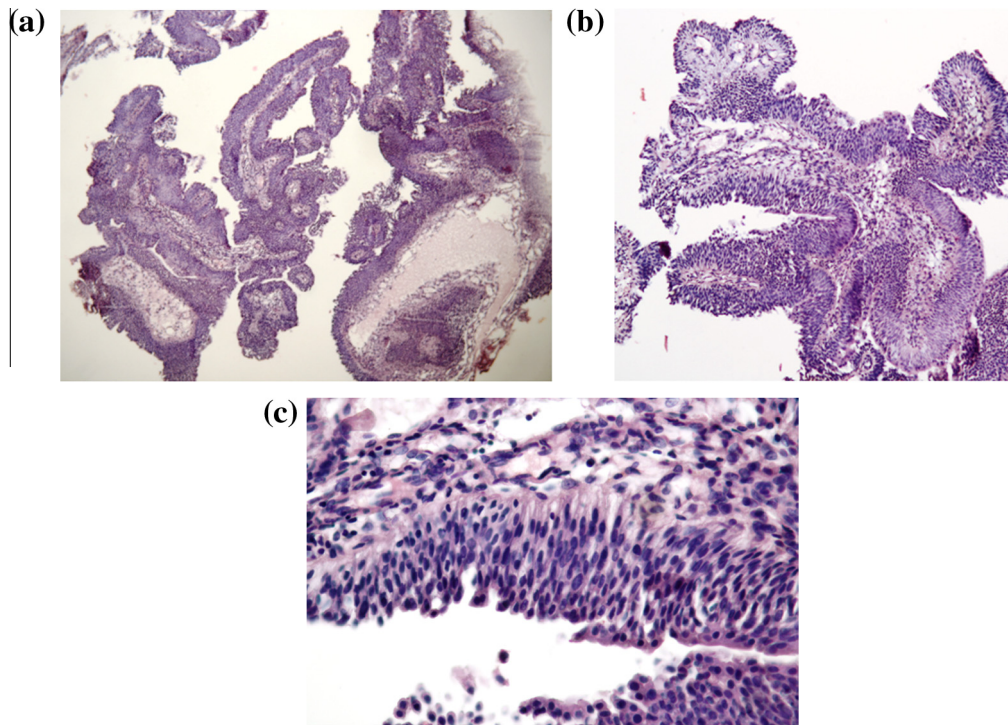


Figure 4 (a–c) Low- ($\times 100$) and high-power ($\times 400$) views showing the histopathology in sections with fragments of ulcerated bladder mucosa with intense mixed acute and chronic inflammatory infiltrate. There was one small fragment of papillary urothelium with enlarged crowded nuclei, consistent with low-grade papillary urothelial carcinoma. There was no stromal invasion. Haematoxylin and eosin stain.

appendectomy and tonsillectomy. He also had treatment for rheumatic fever. US and pelvic MRI showed a 2×1 cm posterior wall tumour. Cystoscopy was first used 3 months earlier in another hospital and revealed a fungating tumour at the left posterolateral wall near the left ureteric orifice. He underwent transurethral resection of the bladder tumour (TURBT), and the histopathology showed a papillary TCC of low grade and no stromal invasion.

In a reassessment, US showed a soft-tissue lesion in the left bladder wall (Fig. 2). Cystoscopy (Fig. 3) showed a villous lesion above the left ureteric orifice of $\approx 2 \times 2$ cm in diameter. The tumour was resected (TURBT) and the bed cauterised.

The histopathology showed fragments of ulcerated bladder mucosa with intense mixed acute and chronic inflammatory infiltrate (Fig. 4a–c). There was one small fragment of papillary urothelium with enlarged crowded nuclei, consistent with low-grade papillary urothelial carcinoma (UC). There was no stromal invasion. The child is currently asymptomatic and follow-up cystoscopy is scheduled.

Discussion

True urinary bladder UC in children is very unusual [50], although there are occasional cases. In 1969, Javadpour and Mostofi [2] identified 40 primary epithelial bladder tumours in patients in the first two decades of life, from 10,000 total cases. Most cases [34] were

papillary, in patients aged 6–20 years, and who presented with gross haematuria. In the first decade of life, primary bladder carcinoma was suggested to be even more uncommon [10], with 30% of cases in children aged ≤ 10 years [49].

Williamson et al. [50] warned that the diagnosis of urothelial tumours in children might be delayed. Urologists might be reluctant to evaluate these patients. The biological behaviour of the tumour must also be considered; the tumour might be of low grade but a follow-up is needed, especially in cases of multiple tumours.

Molecular studies suggest that tumours in children differ in their pathways from those in adult patients. Fine et al. [19] reported a series of 23 urothelial neoplasms in patients aged ≤ 20 years. They confirmed that these tumours were of low grade and had a low risk of recurrence.

Alanee and Shukla [49] identified 140 cases of bladder cancer, with PUNLMP and rhabdomyosarcoma comprising 50.7% and 36.4% of the tumours, respectively. Between 1973 and 2003 the incidence of bladder malignancies increased significantly. The conditional survival calculated for 1 and 2 years after diagnosis was 93.6% and 97.5%. Fifty-one cases of embryonal rhabdomyosarcoma were identified. Reviewing the Surveillance, Epidemiology and End Results (SEER) database, they found that bladder cancer in children aged < 18 years was rare, with only 140 patients registered in the SEER database during the period assessed. The results were consistent with previous multi-institutional studies for

the higher incidence of PUNLMP in children. They also confirmed a high incidence of these tumours in males (male: female ratio, 3:1).

In the present review we excluded those patients with PUNLMP in the series reported by Alanee and Shukla [49], as there is controversy about the diagnosis of PUNLMP and its accuracy in the SEER registry. The term PUNLMP was only introduced in 2004. In the same study, the survival curves should be considered carefully, as the addition of higher-grade tumours is a limiting factor. Furthermore, based on SEER analysis, there might have been errors in reporting one or more parameters of the malignancies [49].

Data on the molecular characteristics and clinical behaviour of bladder tumours in children are less well understood than those of adult/elderly patients [50,51].

As for the follow-up assessments, CT and virtual cystoscopy are much less invasive [52]. For practical purposes [53–55] patients with PUNLMP should be treated similarly to patients with low-grade, noninvasive UC. Molecular grading of these tumours can be used to further assess their biological potential [56].

Because of the low but definite risk of recurrence and grade progression, an appropriate clinical follow-up of patients with primary PUNLMP is warranted [57]. The 1998 WHO/ISUP classification of urothelial neoplasms can be applied reproducibly by pathologists, with a moderate level of agreement. PUNLMP lesions have a more sedate clinical behaviour than UCs but the hazard of recurrence and progression remains, and thus a follow-up is important [57].

In the present report we included articles that were registered after 2004, as was one of the present cases (PUNLMP), but cases of PUNLMP before 2004 were not included.

A univariate analysis [51] showed that high Ki67 expression and low cyclin D1 immunohistological expression were associated with a greater risk of recurrence in the ‘young’ group, while reduced p27Kip1 expression and p53 overexpression were not. By contrast, reduced p27Kip1 expression correlated with a greater risk of recurrence in elderly patients, suggesting that distinct molecular pathways might be involved in the development and progression of these tumours.

In the hereditary nonpolyposis colorectal cancer syndrome, there is a predisposition to urinary tract involvement [51], but there could be an incidence of urothelial tumours in Costello syndrome [22].

It appears that multiple tumours might be more likely to recur, and thus a periodic follow-up is mandatory. Cystoscopy in children is an invasive procedure that requires general anaesthesia, but it cannot be replaced by US and urine cytology. The present study has limitations, because it was retrospective and many abstracts were not available.

Funding

None.

Conflict of interest

None.

References

- [1] Neogi S, Kariholu PL, Dhakre G, Gupta V, Agarwal N, Bhadani P. Malignant urothelial carcinoma of urinary bladder in a young child: a rare case report. *Urology* 2013;**81**:888–90.
- [2] Javadpour N, Mostofi FK. Primary epithelial tumors of the bladder in the first decade of life. *J Urol* 1969;**101**:706–10.
- [3] Lerena J, Krauel L, García-Aparicio L, Vallasciani S, Suñol M, Rodó J. Transitional cell carcinoma of the bladder in children and adolescents: six-case series and review of the literature. *J Ped Urol* 2010;**6**:481–5.
- [4] Bujons A, Caffaratti J, Maria Garat J, Villavicencio H. Long-term follow-up of transitional cell carcinoma of the bladder in childhood. *J Ped Urol* 2013;**20**:1–4.
- [5] Quillin SP, McAlister WH. Transitional cell carcinoma of the bladder in children: radiologic appearance and differential diagnosis. *Urol Radiol* 1991;**13**:107–9.
- [6] Benson Jr RC, Tomera KM, Kelalis PP. Transitional cell carcinoma of the bladder in children and adolescents. *J Urol* 1983;**130**:54–5.
- [7] Yarmohammad A, Ahmadnia H, Asl Zare M. Transitional cell carcinoma in children. report of a case and review of the literature. *Urology* 2005;**2**:120–1.
- [8] Hoenig DM, McRae S, Chen SC, Diamond DA, Rabinowitz R, Caldamone AA. Transitional cell carcinoma of the bladder in the pediatric patient. *J Urol* 1996;**156**:203–5.
- [9] Huppman AR, Pawel BR. Polyps and masses of the pediatric urinary bladder: a 21-year pathology review. *Pediatric Dev Pathol* 2011;**14**:438–44.
- [10] Korreect GS, Minevich EA, Sivan B. High-grade transitional cell carcinoma of the pediatric bladder. *J Ped Urol* 2012;**8**:e36–8.
- [11] Ghousheh AI, Durkee CT, Groth TW. Advanced transitional cell carcinoma of the bladder in a 16-year-old girl with Hinman syndrome. *Urology* 2012;**80**:1141–3.
- [12] Compérat E, Camparo P, Larré S, Roupret M, Neuzillet Y, Pignot G. *Prog Urol* 2013;**23**:171–5.
- [13] Campo G, Giannarini G, Pomara G, Manassero F, Pistolesi D, Selli C. Bladder papilloma in a 9-year-old girl: a case report. *Minerva Pediatr* 2012;**64**:361–3.
- [14] Ruiz E, Alarcón Caba M, Toselli L, Moldes J, Ormaechea M, de Badiola F. Transitional cell carcinoma of the bladder in adolescents: a diagnosis to bear in mind]. *Arch Argent Pediatr* 2009;**107**:49–52.
- [15] Patel R, Tery T, Ninan GK. Transitional cell carcinoma of the bladder in first decade of life. *Pediatr Surg Int* 2008;**24**:1265–8.
- [16] Dowling CR, Reddihough D, Smith P, Webb N, McNeill R, Clouston D. Transitional cell carcinoma in the paediatric population. Be aware of unusual aetiologies. *J Paediatr Child Health* 2007;**43**:773–5.
- [17] Gülpinar O, Soygür T, Baltacı S, Akand M, Kankaya D. Transitional cell carcinoma of bladder with lamina propria invasion in a 10-year-old boy. *Urology* 2006;**68**:2041–3.
- [18] Alam S, Goebel J, Pacheco MC, Sheldon C. Papillary urothelial neoplasm of low malignant potential in a pediatric renal transplant recipient (PUNLMP): a case report. *Pediatr Transplant* 2007;**11**:680–2.

- [19] Fine SW, Humphrey PA, Dehner LP, Amin MB, Epstein JI. Urothelial neoplasms in patients 20 years or younger: a clinicopathological analysis using the World Health Organization 2004 bladder consensus classification. *J Urol* 2005;**174**:1976–80.
- [20] Rodríguez A, Burday D, Sexton W, Ahmad N, Pow-Sang JM. Urothelial carcinoma in a child. *Arch Esp Urol* 2005;**58**:473–5.
- [21] Kilic N, Turkel T, Balkan E, Sevinir B. Transitional cell carcinoma of the bladder presenting after blunt abdominal trauma: a very rare occurrence in childhood. *Int J Urol* 2005;**12**:316–8.
- [22] Urakami S, Igawa M, Shiina H, Shigeno K, Kikuno N, Yoshino T. Recurrent transitional cell carcinoma in a child with the Costello syndrome. *J Urol* 2002;**168**:1133–4.
- [23] Agarwala S, Hemal AK, Seth A, Gupta AK, Bhatnagar V, Mitra DK. Transitional cell carcinoma of the urinary bladder following exposure to cyclophosphamide in childhood. *Eur J Pediatr Surg* 2001;**11**:207–10.
- [24] Mateos Blanco J, Santamaría Ossorio JI, Pimentel Leo JJ, Sanjuán Rodríguez S. Transitional-cell bladder tumor in childhood. *Cir Pediatr* 1999;**12**:168–70.
- [25] Kawaguchi T, Hashimoto Y, Kobayashi H, Kudoh S, Takahashi T, Yanagisawa T. A clinical study of bladder cancer in adolescent patients. *Nippon Hinyokika Gakkai Zasshi* 1999;**90**:614–8.
- [26] Serrano-Durbá A, Domínguez-Hinarejos C, Reig-Ruiz C, Fernández-Córdoba M, García-Ibarra F. Transitional cell carcinoma of the bladder in children. *Scand J Urol Nephrol* 1999;**33**:73–6.
- [27] Muñoz-Delgado Salmerón J, Fernández Arjona M, Shihadeh S, De la Fuente Trabado M, García Estevez JA. Bladder urothelial carcinoma in patients under 10 years of age: report of 2 new cases. *Actas Urol Esp* 1997;**21**:57–9.
- [28] Yusim I, Lismer L, Greenberg G, Haomud K, Kaneti J. Carcinoma of the bladder in patients under 25 years of age. *Scand J Urol Nephrol* 1996;**30**:461–3.
- [29] Curtis M, Schned A, Hakim S, Cendron M. Papillary transitional cell carcinoma of the bladder with lymphangiectasia in an 8-year-old boy. *J Urol* 1996;**156**:202.
- [30] Sánchez Diaz A, de Nova Sánchez E, Fernandez Puentes JC, García López F, Llorens Martínez F, Orduña Domingo A. Transitional cell tumor of the bladder in children: report of a case. *Actas Urol Esp* 1995;**19**:642–5.
- [31] Laurenti C, De Dominicis C, Mattioli D, Rocchegiani A, Franco S, Dal Forno S, Iori F. Transitional cell neoplasm of the bladder in childhood: presentation of a clinical case. *Arch Esp Urol* 1993;**46**:51–4.
- [32] Pastor Guzmán JM, Salinas Sánchez AS, Hernández Millán I, Martínez Martín M, Cañameres Pabolaza L, Virseda Rodríguez JA. Transitional cell tumor of the bladder in childhood. *Actas Urol Esp* 1992;**16**:524–6.
- [33] Wilson-Storey D, Allen AE, Variend S. Transitional cell papillary bladder neoplasm in a girl: an unusual presentation. *J Pediatr Surg* 1992;**27**:113–4.
- [34] Madgar I, Goldwasser B, Nativ O, Hanani Y, Jonas P. Long-term followup of patients less than 30 years old with transitional cell carcinoma of bladder. *J Urol* 1988;**139**:933–4.
- [35] Rayner RJ, Watson AR, Bishop MC. Haematuria in an adolescent due to bladder carcinoma. *Eur J Pediatr* 1988;**147**:328–9.
- [36] Paduano L, Chiella E. Primary epithelial tumors of the bladder in children. *J Urol* 1988;**139**:794–5.
- [37] Madgar I, Nativ O, Hanani Y, Jonas P. Transitional cell carcinoma of the bladder in children under ten years of age. A case report. *Eur Urol* 1988;**14**:216–7.
- [38] Oesterling JE, Epstein JI, Gearhart JP. Transitional cell carcinoma of the bladder in an adolescent with Turner's syndrome. *J Urol* 1987;**137**:398–400.
- [39] Lalmand B, Avni EF, Simon J, Verhest A, Schulman CC, Struyven J. Transitional cell papillary carcinoma of the bladder in a child. *Pediatr Radiol* 1987;**17**:77–9.
- [40] van der Vaeren D, Hennebert P, van Cangh PJ. Epithelial tumors of the bladder in children. Report of 2 cases. *Acta Urol Belg* 1980;**48**:459–63.
- [41] Mauer Mayer W, Tauber R, Steuer G. Epithelial tumors of the urinary bladder in the first twenty years of life (author's transl). *Urologe A* 1977;**16**:286–9.
- [42] Handy PC, Pai MG, Budihal MR, Kaulgud SR. Carcinoma of the bladder in young children: report of 2 cases. *J Urol* 1975;**113**:264–5.
- [43] Castellanos RD, Wakefield PB, Evans AT. Carcinoma of the bladder in children. *J Urol* 1975;**113**:261–3.
- [44] Makler S, Saenz CA. Papillary carcinoma in a child. *Rev Argent Urol Nefrol* 1970;**39**:228–30.
- [45] Rossi MB, Wogalter H, Spatz M. Papillary transitional cell tumor of bladder in a 5-year-old boy. *J Urol* 1967;**97**:88–9.
- [46] Johnson AJ, Taylor JN. Papillary tumor of bladder in a twelve-year-old boy. *J Urol* 1962;**87**:869–70.
- [47] Bujons A, Caffaratti J, Garat JM, Villavicencio H. Long-term follow-up of transitional cell carcinoma of the bladder in childhood. *J Pediatr Urol* 2014;**10**:167–70.
- [48] DeLair SM, White RW, Kurzrock EA. Secondary transitional cell carcinoma and nitrogen mustard treatment. *Urology* 2005;**65**:1226–7.
- [49] Alanee S, Shukla AR. Bladder malignancies in children aged <18 years. Results from the surveillance, epidemiology end results database. *BJU Int* 2009;**106**:557–60.
- [50] Williamson SR, Lopez-Beltran A, MacLennan GT, Montironi R, Cheng L. Unique clinicopathologic and molecular characteristics of urinary bladder tumors in children and young adults. *Urol Oncol Semin Orig Invest* 2013;**31**:414–26.
- [51] Keetch DW, Manley CB, Catalona WJ. Transitional cell carcinoma of bladder in children and adolescents. *Urology* 1993;**42**:447–9.
- [52] Gabr AH, Elbadry M, Elsherief A, Tawfik R. Computed tomography-virtual cystoscopy in the evaluation of a bladder mass: could it replace standard conventional cystoscopy? *Arab J Urol* 2013;**11**:369–74.
- [53] Yanase M, Tsukamoto T, Kumamoto Y, Takagi Y, Mikuma N, Iwasawa A, et al. Transitional cell carcinoma of the bladder or renal pelvis in children. *Eur Urol* 1991;**19**:312–4.
- [54] Khasidy LR, Khashu B, Mallett EC, Kaplan GW, Brock WA. Transitional cell carcinoma of bladder in children. *Urology* 1990;**35**:142–4.
- [55] Gripp KW, Scott Jr CI, Nicholson L, Figueroa TE. Second case of bladder carcinoma in a patient with Costello syndrome. *Am J Med Genet* 2000;**90**:256–9.
- [56] Jones TD, Cheng L. Papillary urothelial neoplasm of low malignant potential: evolving terminology and concepts. *J Urol* 2006;**175**:1995–2003.
- [57] Lee TK, Chaux A. Papillary urothelial neoplasm of low malignant potential of the urinary bladder: clinicopathologic and outcome analysis from a single academic center. *Human Pathol* 2011;**42**:1799–803.